



Full Abdominoplasty With Circumferential Lipoplasty

Lázaro Cárdenas-Camarena, MD; and Victor Laguna-Barraza, MD

Dr. Cárdenas-Camarena is from the Instituto Jalisciense de Cirugía Reconstructiva in Guadalajara, Jalisco, México. Dr. Laguna-Barraza is in private practice in Colima, Mexico. The authors are members of the Mexican Association of Plastic, Aesthetic and Reconstructive Surgery.

Background: The advent of lipoplasty has led plastic surgeons to significantly modify the techniques used in performance of abdominoplasty. Such changes have achieved marked improvement in aesthetic results.

Objective: The authors report their experience in performing combination abdominoplasty and lipoplasty, with particular emphasis on means of reducing complications and obtaining the best results.

Methods: Between May 2004 and November 2006, 122 women underwent abdominoplasty and circumferential lipoplasty combined in a single surgical procedure. Undermining was performed up to the xiphoid process but was limited to the central abdominal area of the flap. Circumferential lipoplasty included treatment of the back and flanks, as well as the abdominal flap.

Results: Between 3100 and 13,200 mL (average, 5800 mL) were obtained through lipoplasty. The abdominoplasty flap weight fluctuated between 650 and 4200 g (average 1050 g). The amount of material obtained through lipoplasty of the central abdominal area corresponded to the abdominoplasty flap weight, fluctuating between 800 and 3600 mL (average, 1700 mL). No major complications (necrosis, damage to the flap, hematoma, postsurgical infection) occurred in our series.

Conclusions: Combination abdominoplasty and circumferential lipoplasty, including lipoplasty of the flap, can be performed safely, with pleasing results and minimal complications. (Aesthetic Surg J 2007;27:493–500.)

The evolution of lipoplasty technique¹ has in turn led to significant modifications in many plastic surgical procedures. One of the most important of these has been the performance of combination abdominoplasty and lipoplasty.²⁻¹⁴

Initially, the role of lipoplasty was quite limited, and it was considered highly risky to perform abdominoplasty in combination with lipoplasty.²⁻⁴ Because lipoplasty on the abdominal flap was generally avoided, some degree of lipodystrophy in the medial area persisted in many patients (Figure 1). The principal issue was the risk of vascular alterations affecting the abdominal flap.^{2,3}

However, with the passage of time the use of combined abdominoplasty and lipoplasty has been extended. Initially, limited lipoplasty was done only in areas adjacent to the abdomen.^{2,4} Later, it had more widespread application, covering the abdominal region but without touching the abdominoplasty flap.⁵ Currently, lipoplasty of the entire abdominal area is performed in combination with abdominoplasty by numerous surgeons.⁶⁻¹⁰

In this article, we review our surgical experience in performing abdominoplasty and circumferential lipoplasty, including lipoplasty of the abdominal flap area, in more than 100 patients, and indicate the measures that

should be taken to avoid complications and obtain the best results.

Materials and Methods

A series of 122 female patients underwent combination abdominoplasty and lipoplasty between May 2004 and November 2006. Patient ages ranged from 27 to 58 years (mean 36 years). The preoperative weight of the patients varied between 123.5 and 189.6 lb (56 and 86 kg; mean 147.7 lb [67 kg]). According to body mass index (BMI), 15 patients (12%) were considered to be at their ideal weight, 95 patients (78%) were overweight (BMI between 25 and 30 kg/m²), and 12 (10%) were obese (BMI higher than 30 kg/m²).

All patients were assessed before surgery by an internist, who performed a cardiologic assessment and paraclinical examinations. The examinations consisted of hematic biometry, prothrombin time, partial thromboplastin time, blood chemistry, and general urinalysis. Before surgery compression garments were placed on the lower extremities of all patients and remained in place until the patient began to walk 1 day after surgery. If preoperative examination revealed a heightened risk for deep venous thrombosis, subcutaneous nadroparin calci-

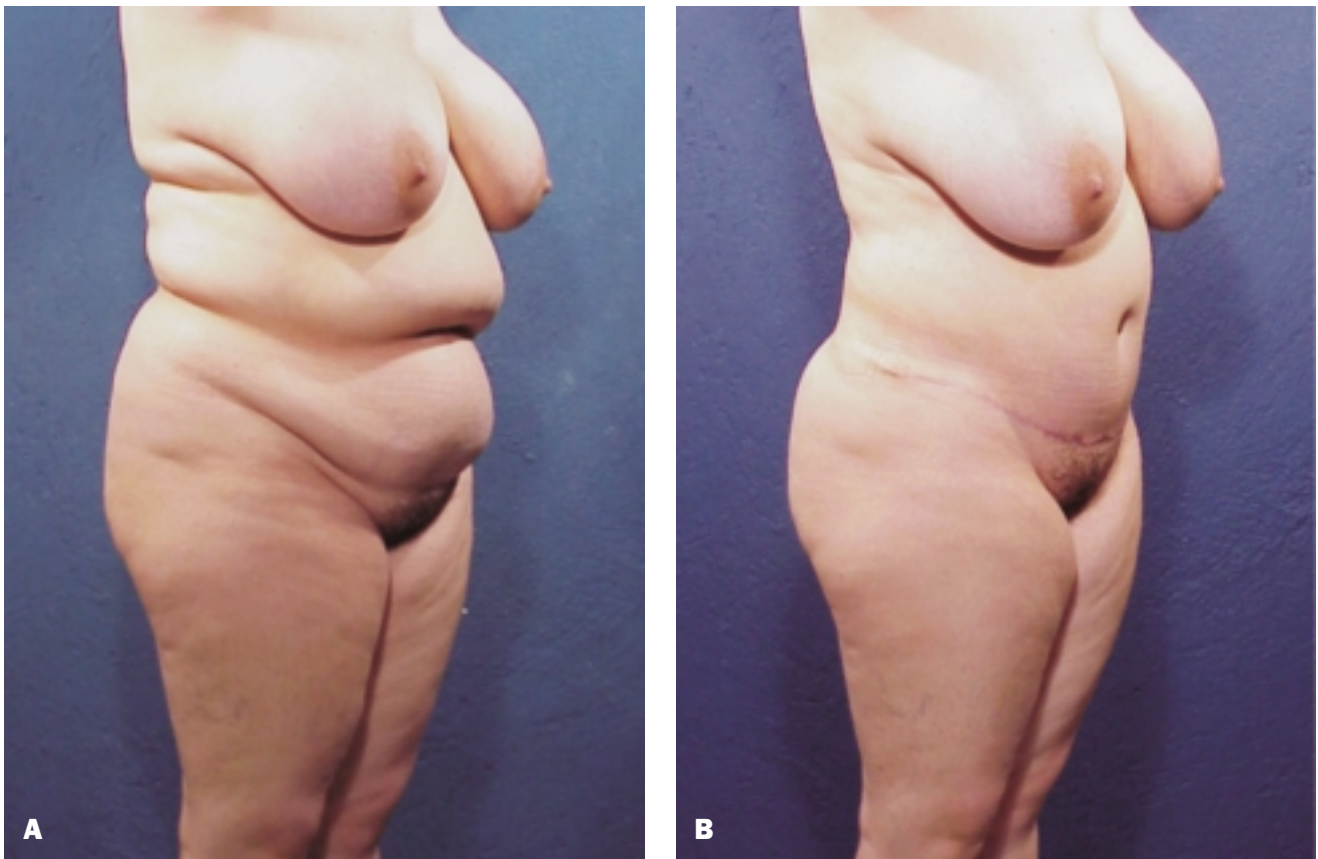


Figure 1. A, Preoperative view of a 34-year-old woman. **B,** Postoperative view 6 months after combined abdominoplasty and circumferential lipoplasty without lipoplasty of the abdominal flap. Some lipodystrophy is still present in the medial abdominal area.

um 3800 anti-factor Xa IU/0.4 mL was administered 2 hours before surgery and was continued daily for 3 days.

The area to be liposuctioned was marked with the patient standing. In the posterior region, the lipoplasty extended from the upper portion of the dorsal area to the supragluteal lumbar region, including the axillary region and flanks. In the anterior region, lipoplasty was performed in the flanks and the abdominal area, including the abdominoplasty flap.

The surgical procedure was performed with an epidural block, leaving the catheter in place for the first 24 hours after surgery for analgesia. The use of an epidural block avoided the need for large amounts of lidocaine in the infiltrating solutions for lipoplasty.

Surgery was initiated with the patient in the ventral decubitus position. Infiltration to achieve tumescence in the operative area was performed, with 0.9% saline solution plus 1 adrenaline ampoule, at an approximate ratio of 1.2 to 1 (ie, 1.2 L of solution per 1 L of material to be liposuctioned). Lipoplasty was initiated with 4-mm can-

nulas in the deep plane and was completed in the superficial plane with 3-mm cannulas, leaving the flap with an approximate thickness of 2 cm, with thickness being calculated by the pinch test. Soft silicone open drains were left in the intergluteal incision used for lipoplasty. Tumescence infiltration was performed in the anterior region with the same parameters as in the posterior region. Lipoplasty was performed in the flanks, thinning them the same way as in the posterior region. The area treated extended to the mid-mammary line. In the central abdominal area, which is located between the two mid-mammary lines, lipoplasty was performed in an intermediate plane, in a single inferosuperior direction, leaving the flap with a greater thickness (approximately 3 cm) than the rest of the liposuctioned area.

Abdominoplasty was initiated after the completion of lipoplasty, with the incision designed according to the requirements of each patient. The flap was completely undermined up to the xiphoid process of the sternum. The fundamental premise underlying this technique was

to limit the supraumbilical undermining to the central portion of the abdominal flap, as we described nearly 10 years ago.¹⁵ Undermining was performed only to the internal edge of the rectus abdominis muscles, the extent necessary to perform plication of their medial edges. Plication was performed with a first plane of separate sutures of absorbable material (Vicryl 0) and a second plane of continuous sutures of nonabsorbable material (Prolene 1). With the patient in the semiflexed position, the excess abdominal flap was then excised. The central portion of the supraumbilical flap and the entire infraumbilical portion was attached to the muscle fascia with Vicryl 0 sutures, as described by Baroudi and Ferreira.¹⁶ A soft silicone negative suction drain was left in place, drawing it out through one side of the wound. The wound was closed in planes with absorbable material (Monocryl 1, 00, 000). The surgery was performed by 2 plastic surgeons. Lipoplasty was performed at the same time by the 2 surgeons, always directed by the senior author (LCC). The abdominoplasty was performed by the senior author with the assistance of the co-author. Duration of surgery was between 3 and 3.5 hours.

The patient remained hospitalized for 24 to 36 hours. Perambulation was initiated 12 hours after surgery to improve blood circulation in the lower extremities and diminish the risk of thrombosis. To avoid intravascular concentration, we continued to administer intravenous fluids until the patient's oral intake was normalized. During this time, an average of 3000 mL crystalloids was administered within 24 hours. Analgesics were administered through the epidural catheter, which was removed 24 hours after surgery. Drains remained in place for 5 to 7 days after surgery, depending on the residual outputs. Pressotherapy with a special compression girdle was indicated on the fifth day and was used for 6 weeks after surgery. Therapeutic ultrasound scanning was initiated on the fifth day, with treatments at 3-day intervals for 1 month. Subdermal therapy was initiated, according to the patient's tolerance, beginning approximately at the third week after surgery and was continued for 1 month.

Results

During the surgical procedure, approximately 3100 to 13,200 mL (average, 5800 mL) was obtained through lipoplasty; the range of aspirated fat removed was 2300 and 9100 mL (average, 4700 mL). The weight of the flap fluctuated between 650 and 4200 g (average, 1050 g). The amount of material liposuctioned in the central abdominal area specifically, corresponding to the abdominoplasty flap, fluctuated between 800 and 3600 mL (average, 1700 mL).

In our series, 11 patients (9%) required administration of 1 unit of globular package immediately after operation, and 2 patients (1.6%) required administration of 2 packages. Eleven of these 13 patients were managed through autodonation. There were no complications associated with the use of the epidural block.

Postoperative complications were minor. There was no necrosis or damage from the flap, hematoma, or post-surgical infection. The most serious complication was the presence of a seroma in the lumbar region in eight patients (6.5%), which resolved satisfactorily through drainage of the seroma in all cases. Visible or palpable irregularities, overcorrection, or asymmetry of scars were present in 11 patients (9%). Nearly all patients (94%) expressed complete satisfaction with the result of the surgery performed, as determined by a patient survey conducted 6 months postoperatively. Representative cases are illustrated in [Figures 2 to 5](#).

Discussion

Performance of combined abdominoplasty and lipoplasty is occurring more and more frequently.¹⁷ Although there are currently some authors who argue that such combination procedures increase mortality rates and result in patient satisfaction only with difficulty,¹³ most aesthetic surgeons believe that the procedures are safe and provide satisfactory improvement.⁵⁻¹² Several authors have confirmed the existence of vascular abdominal support for performance of lipoplasty of the abdominal flap at the same time as abdominoplasty. Saldanha et al⁶ and Graf et al⁷ demonstrated in clinical series and anatomopathologic studies that limiting undermining of the abdominal flap to a very narrow central portion is the prime factor for preserving adequate vascularity of the flap. This is applicable even when extensive lipoplasty of the flap is performed. We reported this point almost 10 years ago,¹⁵ and we still stress it in our publications on the topic.^{16,18} The undermining should be limited to only what is necessary to perform plication of the rectus abdominis muscles. Therefore undermining should be limited by the internal edge of those muscles.

Performance of limited undermining and plication of the rectus muscles without lipoplasty causes bulging of the mid-epigastric area by the existing fat. However, lipoplasty of the flap allows us to eliminate this problem as well. By using sutures to attach the flap to the fascia as described by Baroudi and Ferreira¹⁶ and thinning the abdominal flap by lipoplasty, significant overlapping of the mid-abdominal line is achieved. This overlapping resembles the midline of the rectus muscles, which for many patients is a very pleasing result.

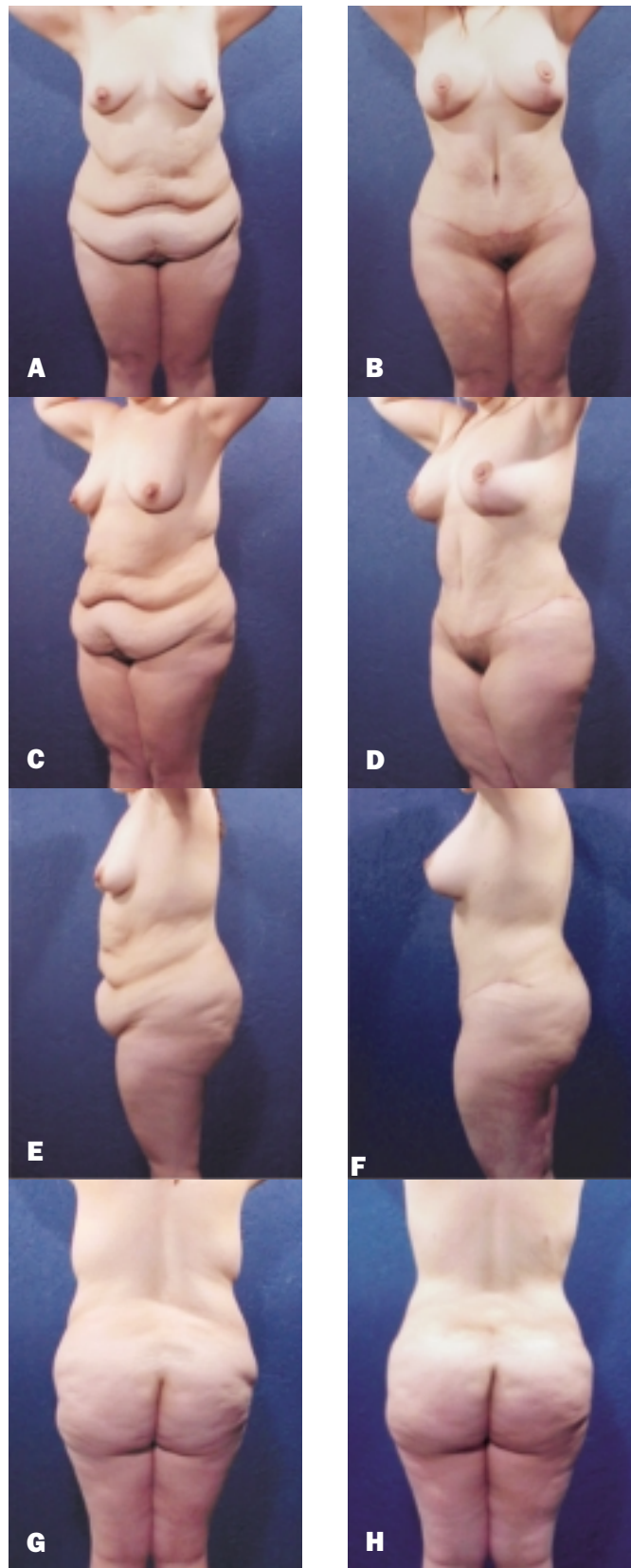


Figure 2. A, C, E, G, Preoperative views of a 26-year-old woman. **B, D, F, H,** Postoperative views 8 months after combined abdominoplasty and circumferential lipoplasty. The amount of fat obtained from the abdominal flap by lipoplasty was 2600 mL.

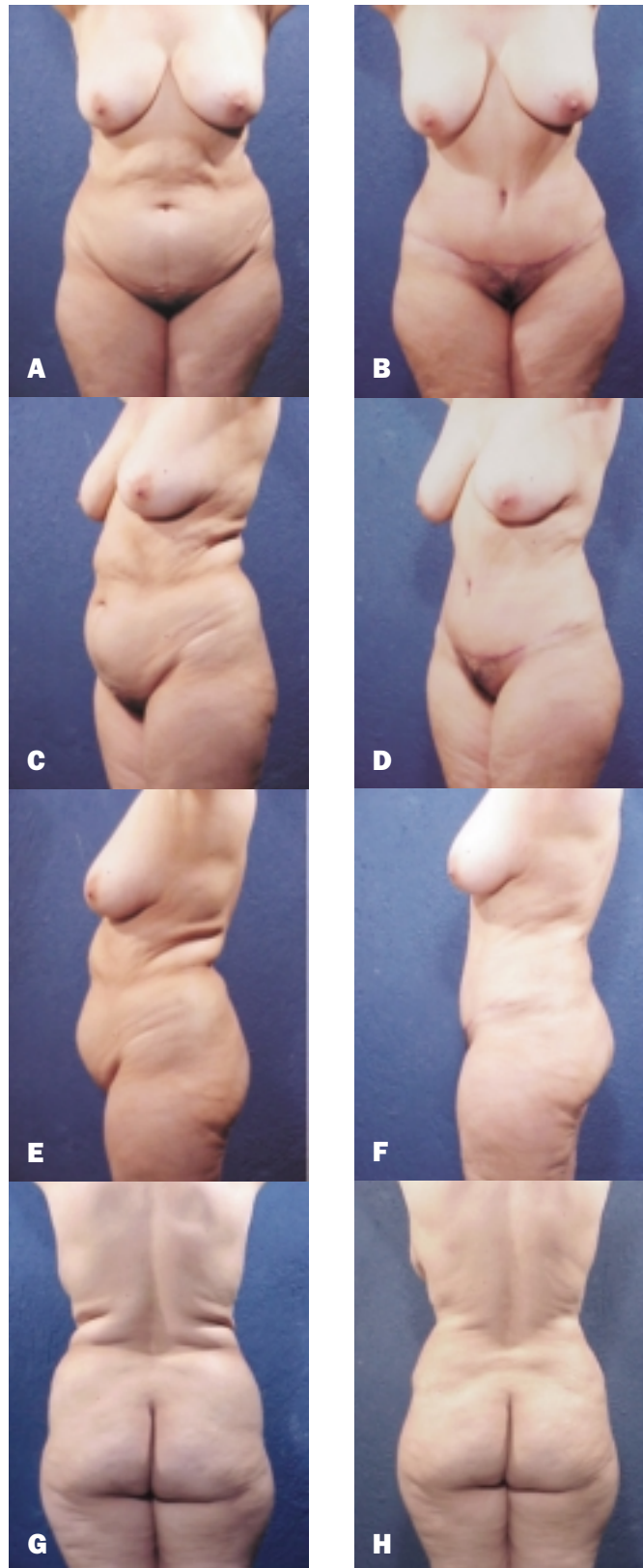


Figure 3. A, C, E, G, Preoperative views of a 46-year-old woman. **B, D, F, H,** Postoperative views 5 months after combined abdominoplasty and circumferential lipoplasty. This patient had significant lipodystrophy throughout the abdominal area. Noteworthy improvement was obtained through lipoplasty of the abdominal flap.

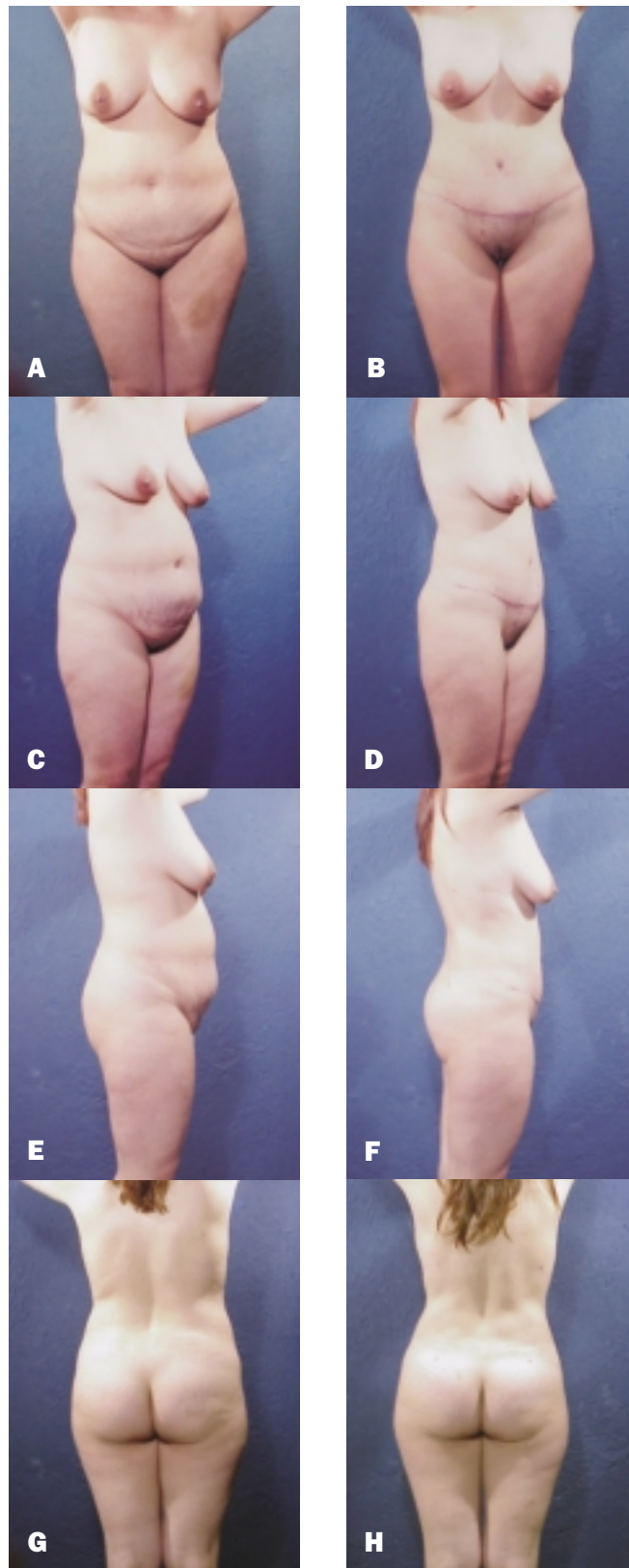


Figure 4. A, C, E, G, Preoperative views of a 28-year-old woman. B, D, F, H, Postoperative views 6 months after combined abdominoplasty with circumferential lipoplasty. The improvement of the lipodystrophy on the abdominal flap was obtained by lipoplasty. As in the patients illustrated in Figures 2 and 3, marked improvement in body contour was achieved by performance of circumferential lipoplasty.

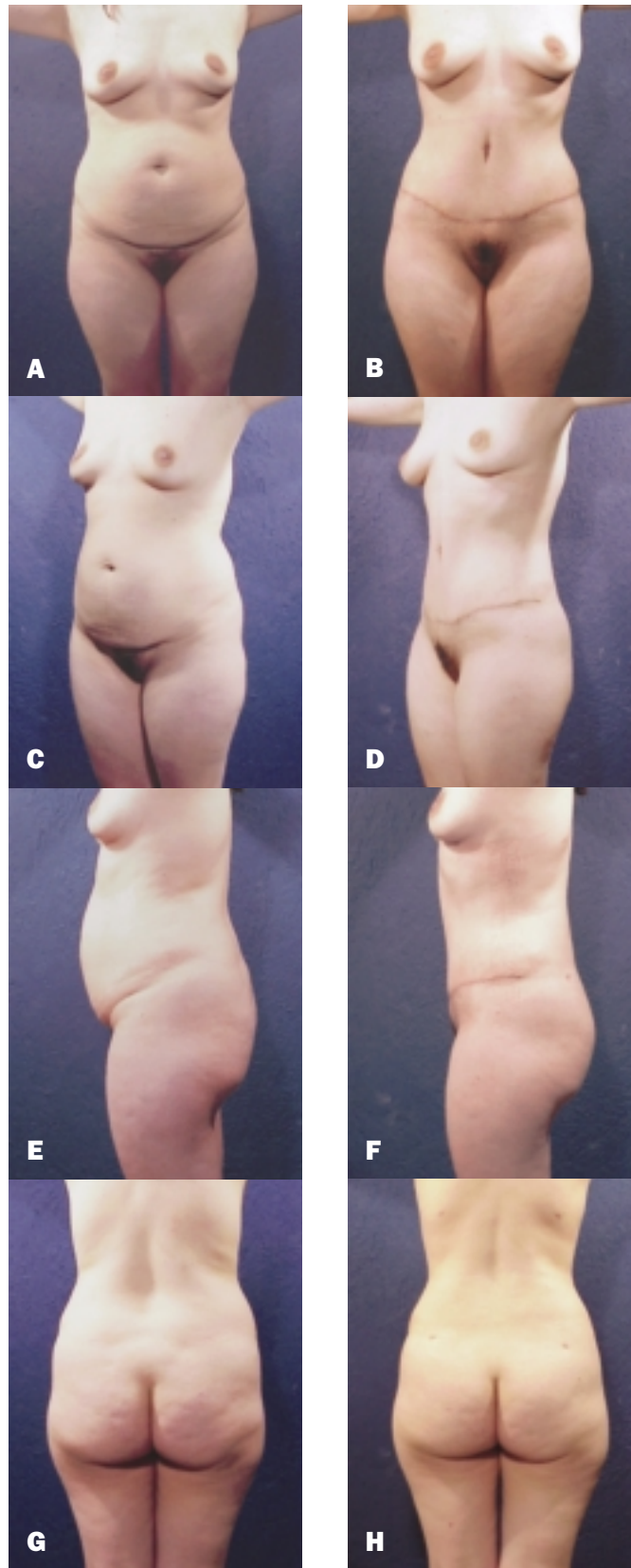


Figure 5. A, C, E, G, Preoperative views of a 33-year-old woman. **B, D, F, H,** Postoperative views 3 months after combined abdominoplasty with circumferential lipoplasty. Note the improved contour of the abdominal area achieved by circumferential lipoplasty of the abdominal flap.

Although combination abdominoplasty and lipoplasty represents a more aggressive approach to body contouring, it does not increase the number of complications. On the contrary, the complication rate has been reduced, compared with our previous reports.^{5,15-20} Currently, we perform lipoplasty and resect amounts that are similar to our initial reports,^{15,20} we undermine the flap only enough to achieve dermofat mobility and umbilical repositioning, and we experience no additional complications in spite of performing lipoplasty. We emphasize that the foundation for this success is central and limited undermining of the flap, which enables preservation of the important flap blood vessels.

Unlike Saldanha et al,⁶ we do not leave any fatty tissue in the infraumbilical portion. They discussed preserving the fatty tissue from Scarpa's fascia downward, attached to the muscle fascia, and removing only the fatty tissue from this fascia up to the skin. The motive for this approach was to avoid steps at the abdominoplasty scar level, because the liposuctioned flap theoretically would be thinner than tissue at the pubic level. Therefore advancing a thin flap by lipoplasty over a thicker tissue might leave an unaesthetic step-off. However, we have not found this problem in our patients, because any step-off that does exist is minimal, and we remove it by liposuctioning the portion from the mound of Venus. Saldanha et al⁶ also sought to preserve maximum sensitivity; we do not believe that retention of so much fat has a substantial impact on this issue.

Conclusion

In our experience, combination abdominoplasty and circumferential lipoplasty, including lipoplasty of the abdominal flap, is a safe procedure that achieves gratifying results. However, to achieve consistent results with a minimum of complications, it is necessary to follow the parameters pointed out in multiple works on the topic. Safety of the vascularity of the flap is achieved by limiting the undermining. An excellent aesthetic result is achieved by a complete thoracoabdominal circumferential lipoplasty that removes the excess abdominal fat often observed in patients undergoing abdominoplasty alone and provides contour in the lumbar area and the flanks. ■

The authors have no financial interest in and received no compensation from manufacturers of products mentioned in this article.

References

- Illouz YG. History and current concepts of lipoplasty. *Clin Plast Surg* 1996;23:721-730.
- Matarasso A. Liposuction as an adjunct to a full abdominoplasty. *Plast Reconstr Surg* 1995;95:829-836.
- Dillerud E. Abdominoplasty combined with suction lipoplasty: a study of complications, revisions, and risk factors in 487 cases. *Ann Plast Surg* 1990;25:333-338.
- Ousterhout DK. Combined suction-assisted lipectomy, surgical lipectomy, and surgical abdominoplasty. *Ann Plast Surg* 1990;24:126-132.
- Cardenas-Camarena L. Aesthetic surgery of the thoracoabdominal area combining abdominoplasty and circumferential lipoplasty: 7 years' experience. *Plast Reconstr Surg* 2005;116:881-890.
- Saldanha OR, De Souza Pinto EB, Mattos WN Jr, Pazetti CE, Lopes Bello EM, Rojas Y, et al. Lipoabdominoplasty with selective and safe undermining. *Aesthetic Plast Surg* 2003;27:322-327.
- Graf R, de Araujo LR, Rippel R, Neto LG, Pace DT, Cruz GA. Lipoabdominoplasty: liposuction with reduced undermining and traditional abdominal skin flap resection. *Aesthetic Plast Surg* 2006;30:1-8.
- Avelar JM. Abdominoplasty combined with lipoplasty without panniculus undermining: abdominoplasty—a safe technique. *Clin Plast Surg* 2006;33:79-90, vii.
- Avelar JM. Abdominoplasty without panniculus undermining and resection: analysis and 3-year follow-up of 97 consecutive cases. *Aesthetic Surg J* 2002;22:16-25.
- Espinosa-de-los-Monteros A, de la Torre JI, Rosenberg LZ, Ahumada LA, Stoff A, Williams EH, et al. Abdominoplasty with total abdominal liposuction for patients with massive weight loss. *Aesthetic Plast Surg* 2006;30:42-46.
- Walgenbach KJ, Shestak KC. "Marriage" abdominoplasty: body contouring with limited scars combining mini-abdominoplasty and liposuction. *Clin Plast Surg* 2004;31:571-581.
- Brauman D. Liposuction abdominoplasty: an evolving concept. *Plast Reconstr Surg* 2003;112:288-298.
- Hafezi F and Nouhi A. Safe abdominoplasty with extensive liposuctioning. *Ann Plast Surg* 2006;57:149-153.
- Gemperli R, Neves RI, Tuma P Jr, Bonamichi GT, Ferreira MC, Manders EK. Abdominoplasty combined with other intraabdominal procedures. *Ann Plast Surg* 1992;29:18-22.
- Cardenas-Camarena L, Gonzalez LE. Large-volume liposuction and extensive abdominoplasty: a feasible alternative for improving body shape. *Plast Reconstr Surg* 1998;102:1698-1707.
- Baroudi R, Ferreira CA. Contouring the hip and the abdomen. *Clin Plast Surg* 1996;23:551-572.
- American Society of Plastic and Reconstructive Surgeons. Statistics. at <http://www.plasticsurgery.org/media/statistics/loader.cfm?url=/commonspot/security/getfile.cfm&PageID=17870>. Last accessed January 2007.
- Cardenas-Camarena L. Various surgical techniques for improving body contour. *Aesthetic Plast Surg* 2005;29:446-455; discussion 456-459.
- Cardenas-Camarena L. Lipoaspiration and its complications: a safe operation. *Plast Reconstr Surg* 2003;112:1435-1441.
- Cardenas-Camarena L, Tobar-Losada A, Lacouture AM. Large-volume circumferential liposuction with tumescent technique: a sure and viable procedure. *Plast Reconstr Surg* 1999;104:1887-1899.

Accepted for publication July 9, 2007.

Reprint requests: Lázaro Cárdenas-Camarena, MD, Av. Chapalita 1300. Col Chapalita, Guadalajara Jalisco. México 45000.

Copyright © 2007 by The American Society for Aesthetic Plastic Surgery, Inc.

1090-820X/\$32.00

doi:10.1016.j.asj.2007.08.002