

Large-Volume Liposuction and Extensive Abdominoplasty: A Feasible Alternative for Improving Body Shape

[Cosmetic]

Cárdenas-Camarena, Lázaro M.D.; González, Luis E. M.D.
Jalisco, Mexico

Plastic Surgery Unit; Av. Chapalita 1300 Col. Chapalita; Guadalajara, Jalisco 4500, México (Cárdenas-Camarena)
From the Reconstructive Surgery Institute of Jalisco.

Received for publication April 14, 1998.

Abstract [TOP](#)

Forty-two female patients underwent liposuction of large volumes and extensive abdominoplasty during an 18-month period, with an average follow-up period of 9 months. Fifty-two percent of the patients underwent a third surgical procedure, which was basically aesthetic. The average age was 40 years; weight varied between 51 kg and 113 kg, with only 11 percent of the patients at their ideal weight. The tumescent technique was used for performing liposuction, which was done on the loins, trochanters, lumbar, upper scapular, and upper lateral abdominal regions, avoiding liposuction of the abdominal flap in all cases except for one. The abdominoplasty was extensive with detachment to the xiphoid process without detaching liposuctioned areas. Volumes of 1600 ml to 11,200 ml were obtained through liposuction, with an average of 4230 cc, and minimal blood loss. Fatty dermal tissue was removed through abdominoplasty and it varied between 400 g and 5000 g with an average of 1300 g. Only the two heaviest patients required an autologous blood unit, because they underwent breast reduction at the same time. All the other patients were managed exclusively with intravenous crystalloids solutions. No major complications arose, and only five patients had minor complications. Based on these results, we consider it to be feasible to combine the liposuctioning of large volumes with abdominoplasty to improve body shape, even with the addition of a third surgical procedure. Nevertheless, it is essential to use the tumescent technique for liposuction to reduce bleeding to a minimum and to allow us to perform other procedures.

Abdominal surgery for contouring has usually been carried out by means of surgical procedures such as abdominoplasty or, more recently, liposuction.¹⁻³ Several publications study the safety and possible complications of these two surgical procedures separately.⁴⁻⁸ These studies conclude that precise indications, i.e., proper patient selection, good preparation, and continuous patient follow-up, must exist to obtain good results and to avoid complications. With these considerations, an abdominoplasty presents a complication risk factor of up to a 2 percent as an isolated procedure, whereas the incidence with liposuction is only 0.1 percent.⁴ Some authors present results of abdominoplasty combined with other major surgical procedures. These studies contain gynecologic-obstetric, abdominal, and cosmetic⁹⁻¹⁵ procedures combined with other techniques, especially liposuction. On many occasions an abdominoplasty or liposuction alone cannot achieve satisfactory aesthetic results. This finding may be attributable to a very thick abdominal flap or to significant amounts of fat in body areas such as the loins, waist, hips, or lumbar region. Although the safety of these two aesthetic procedures has been clearly established, there are some doubts concerning the safety of combining them into one surgical procedure, concerns being even greater when the two procedures are carried out in an extensive manner sometimes even with a third procedure added to the combination.^{6,9,12} This article studies 42 patients who underwent total abdominoplasty and large-volume liposuction. More than half of this group of patients also had a third surgical procedure.

Clinical Cases [TOP](#)

During an 18-month period, from July of 1996 to December of 1997, 42 female patients underwent abdominoplasty together with large-volume liposuction (>1,500 ml). Liposuction was done on the loins and the thoracic, scapular, lumbar, and trochanteric regions. Ages ranged from 26 to 64 years of age, with an average age of 40 years. The preoperative weight of the patients varied between 51 and 113 kg, with an average weight of 71 kg. With respect to G. W. Thorn's size-weight relationship,¹⁶ only 11 percent of the patients were considered to be at their ideal weight. Eight patients were heavy smokers, consuming more than 10 cigarettes per day; it was recommended that they quit smoking 2 weeks before the surgery. Three patients had a high transverse abdominal scar resulting from a cholecystectomy carried out more than 2 years before. All the patients underwent preoperative laboratory tests, including hemoglobin, hematocrit, prothrombin time, partial thromboplastin time, glucose determination, serum creatinine and urea, and general urine analysis. Those patients older than 45 years of age or with a significant medical history underwent a thorough preoperative assessment by an internal

Article Outline

[Abstract](#)

[Clinical Cases](#)

[Surgical Technique](#)

[Results](#)

[Discussion](#)

[Acknowledgments](#)

[REFERENCES](#)

Figures/Tables

[TABLE I Additional S...](#)

[TABLE II Complicatio...](#)

[Fig. 1](#)

[Fig. 2](#)

[Fig. 3](#)

[Fig. 4](#)

[Fig. 5](#)

[Fig. 6](#)

[Fig. 7](#)

[Fig. 8](#)

[Fig. 9](#)

[Fig. 10](#)

[Fig. 11](#)

[Fig. 12](#)

medicine consultant, including a rest electrocardiogram. Twenty-two of the patients underwent an additional surgical procedure, including procedures such as mastopexis, placement of breast implants, and breast reduction ([Table I](#)).

Procedure	Patients
Mastopexy	7
Breast implant placement	4
Breast reduction	3
Gluteal liposuction	2
Vaginoplasty	2
Umbilical hernioplasty	2
Rhinoplasty	2

TABLE I Additional Surgical Procedures

Surgical Technique [TOP](#)

Six hours before surgery, all the patients receive prophylactic antibiotic therapy (1 gm of cephalexine), which was continued for 24 hours postoperatively. One gram of hydrocortisone is administered once immediately before surgery. All the patients were given regional anesthesia by means of a peridural block with lidocaine. In cases in which additional procedures were carried out such as in the mammary regions or the face, local anesthesia was used with 0.5% lidocaine plus 1:300,000 epinephrine and previous sedation. The areas to be liposuctioned were preoperatively marked with the patient standing on her feet. In only one case, liposuctioning was performed in the flap area of the abdominoplasty. The liposuctioned areas in all cases covered the loins, lateral upper abdomen, lumbar region, lower scapular region and trochanters. Liposuction is carried out after preparing the area with the tumescent technique by infiltrating a solution consisting of 1 liter of 0.9% saline solution plus one ampule of adrenaline. The volume of the infiltrated liquid is an amount similar to what is estimated to be extracted through liposuction. With the patient in a ventral decubitus position, the liposuction is carried out in the lumbar region, lower scapula, loins, and trochanters. Likewise, liposuction is carried out on the inner thighs when indicated. The patient is later turned over to a dorsal decubitus position to finish the liposuction of the loins, trochanters, inner thighs, and upper lateral portions of the abdomen. Once the liposuction is finished, the abdominoplasty is carried out. First, the flap is detached to the xiphoid process without invading the liposuctioned areas. A central plication of the rectus abdominis muscles with nonabsorbable suture no. 1 is made. The patient is flexed, and the excess fatty dermal flap is removed. Posterior and anterior shunts are left in for a 4- to 6-day period. Additional surgical procedures are carried out before the abdominoplasty or subsequent to it, depending on each individual case. The replacement of intravenous liquids is exclusively carried out with crystalloid solutions. This replacement consists of administering intravenously 300 cc of fluids per liter of suctioned fat. An autologous blood pack was administered during surgery only for the two heaviest patients who underwent breast reduction surgery at the same time. The peridural catheter is left in place for 12 hours after surgery for analgesia. The catheter is removed then, and the patient is advised to get out of bed and walk around the next day, being released from the hospital 36 to 48 hours after surgery. All patients are bandaged with a postsurgical compressive bandage in the form of an elastic girdle for a period of 6 weeks after surgery. Therapeutic massages are also recommended for the liposuctioned areas for 15 days starting the second postoperative week.

Results [TOP](#)

The follow-up period for the patients was from 3 to 18 months, with a mean time of 9 months. The postsurgical weight ranged from 47 to 97 kg with a mean weight of 64 kg, giving an average postsurgical weight loss of 7 kg. Nevertheless, the most relevant fact in body shape was the size reduction, which some patients claimed was up to six sizes, although the average reduction was two. Thirty-seven percent of the patients achieved an ideal size-weight relationship after surgery. The amounts extracted by means of liposuction varied between 1600 and 11,200 ml, with an average of 4230 ml. The weight of the tissue extracted in the abdominoplasty varied from 400 and 5000 g, with an average of 1300 g. The decrease in the hemoglobin and hematocrit levels 1 week after surgery averaged 3.4 g and 11 percent, respectively. The most relevant and bothersome postsurgical symptoms for the patients were asthenia and adynamia, which were moderate in 12 cases and more severe in 6 cases. This symptom persisted 9 days on an average in the moderate cases and 14 days in the most severe cases. A distal necrosis of the flap occurred in the only patient who underwent moderate liposuction of the flap area. A decision was made to liposuction this area because the liposuctioning carried out in the other areas was very limited and there was no significant risk factor. Three patients suffered serous fluid accumulation in the area of the abdominoplasty, with an accumulation of 120, 60, and 40 ml in each case. The heaviest patient suffered partial dehiscence of the surgical wound 3 days after the sutures were removed, thus the wound was left to close by second intention. No major complications occurred. A summary of the complications is presented in [Table II](#).

Complication	Patients
Distal necrosis of the flap	1
Serous fluid accumulation	3
Wound dehiscence	1

TABLE II Complications

Discussion [TOP](#)

The problem of body shape has been generally resolved by the development of liposuction. The technique has benefitted from several modifications since its inception, from the dry technique by Fournier¹ until the moist technique by Illouz,² in which the use of thick cannulas in a deep plane is recommended. Later on appeared the use of thin cannulas in a shallow plane.³ Undoubtedly, one of the most significant advances in liposuction has been the use of the tumescent technique for removing fat as described by Klein in 1993.¹⁷ This technique has reduced considerably complications and limitations related to liposuction and with it larger amounts of fat can be removed without blood transfusions. The number of complications is lower and recovery time is shorter. The combination of an abdominoplasty with another major surgical procedure has been described by several authors. Hester et al.⁹ made a very thorough review of his experiences in performing gynecological, abdominal, and aesthetic procedures, including liposuction, together with abdominoplasty. Likewise, there are reports on the combination of abdominoplasty and liposuction, such as offered by Dillerud,¹² Ousterhout,¹³ Illouz,¹⁴ and Matarasso.¹⁵ Despite all these variations, the authors basically recommend liposuctioning the abdominal flap before raising it. The liposuction in other areas is very limited, being carried out mainly on the loins. There are even some authors who recommend that liposuction be relatively reduced in these cases, because the risk of complications otherwise is very high,⁶ and that it should be avoided in patients who are overweight.¹³

The combination of complete abdominoplasty with liposuction of large volumes (>1500 ml) is not accepted by the majority of the authors. In addition, there are no reports of liposuctioning large volumes, performing extensive abdominoplasty, and undertaking a third surgical procedure. Nevertheless, it was possible to carry out these combinations in our study because of various factors that we consider important. When using the tumescent technique in liposuction, the volume of blood loss is considerably less than expected and reported by other authors who use the moist or dry techniques.^{2,7} This method allows us to perform other surgical procedures without needing blood transfusions. Transfusions were only necessary in the two heaviest patients who, in addition to undergoing abdominoplasty and the removal of 11,000 and 9400 ml through liposuction, underwent breast reduction. The liposuction in our patients was done throughout the thoracoabdominal region, extending to trochanteric regions, but it was avoided on the abdominal flap. This method differs from what was reported by all the other authors. We were able to prevent trauma of the abdominal flap and to avoid the possibility of necrosis by not liposuctioning the flap when major liposuction was carried out in the periphery of the abdominal area. The patient who underwent this combination suffered partial necrosis of the flap, with this being the only necrosis that occurred. Likewise, we avoided the risk factor of fat embolism by not performing liposuction on the abdominal flap when extensive liposuction and abdominoplasty had been carried out. The use of a peridural catheter for anesthesia technique and leaving it in to administer postsurgical analgesics negates the need to use lidocaine in the infiltrated liquid for liposuction, which differs from what Klein¹⁷ describes. Based on this and on the studies done by Burk et al.,¹⁸ it was possible for us to carry out a third surgical technique with additional infiltration of lidocaine and epinephrine. The incidence of complications while performing a third surgical technique was no greater than what was reported by other authors carrying out only two procedures. (Figures)

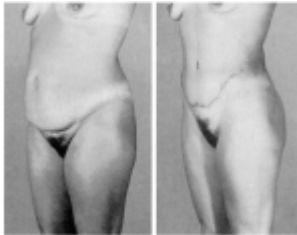


Fig. 1. Patient 1 is a 32-year-old woman. (Left) Preoperative view and (right) at 4 months follow-up.

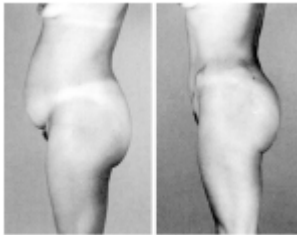


Fig. 2. Patient 1 (left) before and (right) after liposuction of 1600 ml and removal of 450 g through abdominoplasty.

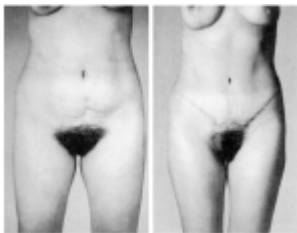


Fig. 3. Patient 2 is a 28-year-old woman. (Left) Preoperative view and (right) at 5 months follow-up.

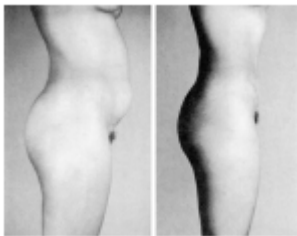


Fig. 4. Patient 2 (left) before and (right) after liposuction of 2000 ml, including trochanters, and removal of 500 g through abdominoplasty.

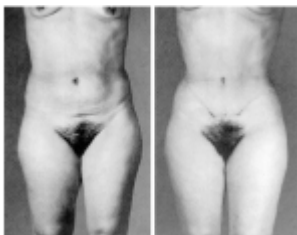


Fig. 5. Patient 3 is a 42-year-old woman. (Left) Preoperative view and (right) at 14 months follow-up.

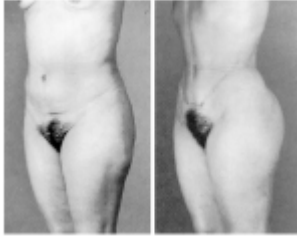

Fig. 6. Patient 3 (*left*) before and (*right*) after liposuction of 5600 ml, including trochanters, and removal of 750 g through abdominoplasty.

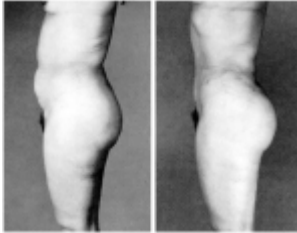


Fig. 7. Patient 3: (*left*) preoperative and (*right*) postoperative side view. This patient also received vaginoplasty at the same time.

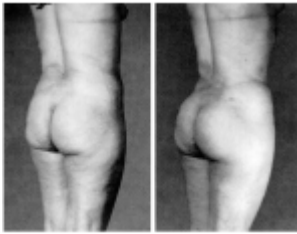


Fig. 8. Patient 3 (*left*) before (*right*) after infiltration of 120 ml of fat into each gluteal region.

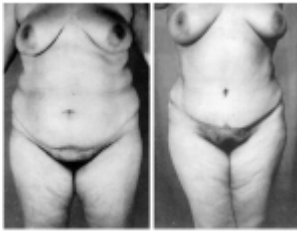

Fig. 9. Patient 4 is a 36-year-old woman. (*Left*) Preoperative view and (*right*) at 5 months follow-up.

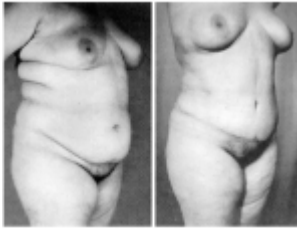

Fig. 10. Patient 4 (*left*) before and (*right*) after liposuction of 8600 ml including trochanters and inner thighs.

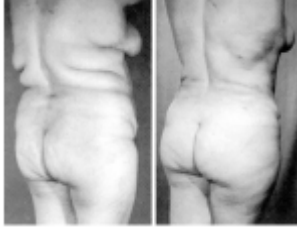

Fig. 11. Patient 4 (*left*) before and (*right*) after removal of 2500 g through abdominoplasty.

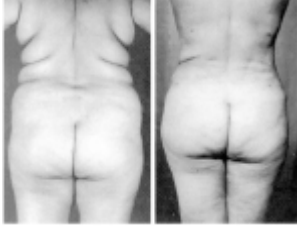

Fig. 12. Patient 4: (*left*) preoperative and (*right*) postoperative back view. This patient also received blepharoplasty at the same time.

Based on the clinical results obtained and the low incidence in complications, we consider it feasible to carry out liposuction of large volumes together with abdominoplasty, with the possibility of being able to add a third surgical procedure, whenever necessary, being gynecologic or aesthetic. However, we emphasize the need to use the tumescent technique for liposuction, because the avoidance of blood loss and the carrying out of minimum-risk procedures depend on it. Each patient undoubtedly must be personally evaluated and assessed. This combination of procedures may be carried out depending on individual characteristics; whenever necessary, do not hesitate to use a pack for autotransfusion when the volume to be liposuctioned is considerable, for the widest margin of safety possible.

Lázaro Cárdenas-Camarena, M.D.

Plastic Surgery Unit; Av. Chapalita 1300 Col. Chapalita; Guadalajara, Jalisco 4500, México

Acknowledgments [TOP](#)

We want to thank Francisco de la Mora G., M.D., anesthesiologist of the Reconstructive Surgery Institute of Jalisco, as well as Francisco Ruvalcaba, M.D., who helped in preparing the photographic material and in the final structuring of the work.

REFERENCES [TOP](#)

1. Fournier, P. F., and Otteni, F. M. Lipodissection in body sculpturing: The dry procedure. *Plast. Reconstr. Surg.* 72: 598, 1983.
[\[Medline Link\]](#) [\[CrossRef\]](#) [\[Context Link\]](#)
2. Illouz, Y. G. Body contouring by lipolysis: A 5-year experience with over 3000 cases. *Plast. Reconstr. Surg.* 72: 591, 1983.
[\[Medline Link\]](#) [\[CrossRef\]](#) [\[Context Link\]](#)
3. Gasperoni, C., Salgarello, M., Emiliozzi, P., and Gargani, G. Subdermal liposuction. *Aesthetic Plast. Surg.* 14: 137, 1990.
[\[Medline Link\]](#) [\[CrossRef\]](#) [\[Context Link\]](#)
4. Teimourian, B., and Rogers, W. B., III. A national survey of complications associated with suction lipectomy: A comparative study. *Plast. Reconstr. Surg.* 84: 628, 1989.
[\[Context Link\]](#)
5. Hunter, G. R., Carpo, R. O., Broadbent, T. R., and Woolf, R. M. Pulmonary complications following abdominal lipectomy. *Plast. Reconstr. Surg.* 71: 809, 1983.
[\[Medline Link\]](#) [\[CrossRef\]](#) [\[Context Link\]](#)
6. Laub, D. R., Jr., and Laub, D. R. Fat embolism syndrome after liposuction: A case report and review of the literature. *Ann. Plast. Surg.* 25: 48, 1990.
[\[CrossRef\]](#) [\[Context Link\]](#)
7. Courtiss, E. H., Choucair, R. J., and Donelan, M. B. Large volume suction lipectomy: An analysis of 108 patients. *Plast. Reconstr. Surg.* 89: 1068, 1992.
[\[Medline Link\]](#) [\[CrossRef\]](#) [\[Context Link\]](#)
8. Grazer, F. M., and Goldwyn, M. Abdominoplasty assessed by survey, with emphasis on complications. *Plast. Reconstr. Surg.* 59: 513, 1977.
[\[Medline Link\]](#) [\[Context Link\]](#)
9. Hester, T. R., Jr., Baird, W., Bostwick, J., III, Nahai, F., and Cukic, J. Abdominoplasty combined with other major surgical procedures: Safe or sorry? *Plast. Reconstr. Surg.* 83: 997, 1989.
[\[Context Link\]](#)
10. Dillerud, E. Complications of suction-assisted abdominoplasty combined with other surgical procedures (Correspondence). *Plast. Reconstr. Surg.* 85: 994, 1990.
[\[Medline Link\]](#) [\[CrossRef\]](#) [\[Context Link\]](#)
11. Hester, T. R., Jr. (Reply) *Plast. Reconstr. Surg.* 85: 995, 1990.
[\[Context Link\]](#)
12. Dillerud, E. Abdominoplasty combined with suction lipoplasty: A study of complications, revisions, and risk factors in 487 cases. *Ann. Plast. Surg.* 25: 333, 1990.
[\[CrossRef\]](#) [\[Context Link\]](#)
13. Ousterhout, D. K. Combined suction-assisted lipectomy, surgical lipectomy and surgical abdominoplasty. *Ann. Plast. Surg.* 24: 126, 1990.
[\[CrossRef\]](#) [\[Context Link\]](#)
14. Illouz, Y. G. A new safe and aesthetic approach to suction abdominoplasty. *Aesthetic Plast. Surg.* 16: 237, 1992.
[\[Medline Link\]](#) [\[CrossRef\]](#) [\[Context Link\]](#)
15. Matarasso, A. Liposuction as an adjunct to full abdominoplasty. *Plast. Reconstr. Surg.* 95: 829, 1995.
[\[CrossRef\]](#) [\[Context Link\]](#)
16. Thorn, G. H., and Cahill, G. F., Jr. Obesity. In *Harrison's Principles of Internal Medicine*. New York: McGraw-Hill, 1977. Pp. 270-275.
[\[Context Link\]](#)
17. Klein, J. A. Tumescent technique for local anesthesia improves safety in large volume liposuction. *Plast. Reconstr. Surg.* 92: 1085, 1993.
[\[CrossRef\]](#) [\[Context Link\]](#)
18. Burk, R. W., III, Guzman-Stein, G., and Vasconez, L. O. Lidocaine and epinephrine levels in tumescent technique liposuction. *Plast. Reconstr. Surg.* 97: 1379, 1996.
[\[Context Link\]](#)