

# Reduction Mammoplasty With Superolateral Dermoglandular Pedicle

## Details of 15 Years of Experience

Lázaro Cárdenas-Camarena, MD\*†‡§¶||

**Abstract:** The techniques of reduction mammoplasty are multiple and varied. Each one has advantages and disadvantages. With any of them, full preservation of vascularity and sensitizing of the nipple-areola complex (NAC) should be sought, as well as functionality of the breast. We present our 15 years' experience using the superolateral dermoglandular pedicle, a technique that fully preserves the integrity of the breast. During that 15-year period, we operated on 702 breasts in 356 patients, using the superolateral dermoglandular pedicle, with the NAC requiring a migration of 5 to 16 cm (mean: 9.2 cm), having resected breast tissue between 300 and 1380 g, (average: 660 g). The technique was used in women between 16 and 63 years of age (average 37), who wanted breast reduction and who required a migration of the NAC greater than 5 cm.

We had minor complications consisting of wound dehiscence (5.9%), scar hyperpigmentation (3.9%), fat necrosis (3.8%), hypertrophic scarring (3.1%), alterations in sensitivity (2.27%), and keloid scarring (0.5%). We had 9 cases of necrosis of the NAC (1.28%), of which 7 were partial (0.99%) and 2 were total (0.28%). Satisfaction with the results was 94%.

The technique of reduction mammoplasty with a superolateral dermoglandular pedicle has been used in mammary hypertrophy and gigantomasty with excellent results. Its design is simple, its performance easy, and its aesthetic results are highly reproducible. The position of the pedicle allows full preservation of the vascularity, sensitivity, and functionality of the breast, and is therefore a highly recommendable technique.

**Key Words:** breast reduction, reduction mammoplasty, superolateral pedicle, dermoglandular pedicle

(*Ann Plast Surg* 2009;63: 000–000)

Although it is evident that the principal function of the mammary gland is lactation, over time this concept has changed significantly. Therefore, the breast is currently considered not only with the specific function of lactation. The breast has sexual and sensual implications, so surgical manipulation of it must always focus on covering these needs to the fullest. Because mammary hypertrophy is one of the more frequent pathologies for the plastic surgeon, reduction mammoplasty techniques are numerous and varied, each one presenting specific advantages and disadvantages.<sup>1</sup> The pres-

ence of multiple surgical techniques only indicates that there not exists an ideal technique for breast reduction. Therefore, when choosing a surgical technique, we should consider all the advantages and disadvantages that each technique presents. Hence, we should try to obtain a pleasing aesthetic result, while preserving the integrity and functionality of the breast. We feel that using a superolateral dermoglandular pedicle provides excellent results obtaining, at the same time, all the objectives that we seek in a reduction mammoplasty. For this reason, we are presenting our 15 years of experience using this technique in over 300 patients, with highly gratifying results, emphasizing the changes that we have made during these years to improve the technique.

### MATERIALS AND METHODS

This is a retrospective study, covering a 15-year period, from April 1992 to March 2008. We performed reduction mammoplasty on 356 patients using a superolateral dermoglandular pedicle. Our first report of this original technique was presented in 2001.<sup>2</sup> The technique has been used on 702 breasts of females between 16 and 63 years of age (average 37). Body Mass Index of the patients was between 20 and 25 in 12%, from 25 to 27.5 in 56%, from 27.6 to 30 in 19%, and over 30 in the remaining 13%, with a mean of 27.2. Of total, 26% were nulliparous, 74% had already been pregnant, 13% were controlled hypertensive, and 5% presented type II diabetes mellitus, controlled with diet and oral hypoglycemics. The surgical indication included all patients who wanted reduction of their breasts and who required migration of the nipple-areola complex (NAC) of more than 5 cm. This technique should not be used in patients whose NAC migration is less than 5 cm, since this can produce torsion of the vascular pedicle and can generate circulatory compromise. We evaluated all patients preoperatively, we investigated about their medical history and surgical expectations, explaining to them the scope, advantages, and disadvantages of the surgical procedure. They underwent paraclinical analysis consisting of complete hematic biometry, coagulation times, blood chemistry, and general urinalysis. When necessary, they were evaluated by an internal medicine specialist, who performed a preoperative cardiology review.

The degree of satisfaction was determined by direct questioning during their consultation at the sixth postoperative month. In the case of longer follow-ups, a new assessment was performed, discarding the previous one. The assessments took into consideration the shape, size, scarring, sensitivity, and ability to lactate in case of pregnancy. The answers to shape, size, and scarring were rated in 5 categories, based on the degree of satisfaction with each concept. The 5 possible answers to the result were: very poor, poor, acceptable, very good, and excellent. The answers acceptable, very good, and excellent, were considered as satisfactory results. The responses poor and very poor were considered as unsatisfactory results. Sensitivity was assessed subjectively by the patient herself in relation to the degree of modification before and after surgery. This assessment was a comparison of before and 6 months following the surgical procedure. The assessment was solely for determining whether

Received June 30, 2008, and accepted for publication, after revision, September 9, 2008.

From the \*International Confederation for Plastic Reconstructive and Aesthetic Surgery (IPRAS); †International Society of Aesthetic Plastic Surgery (ISAPS); ‡Iberolatinoamerican Plastic Surgery Federation (FILACP); §Mexican Association of Plastic Esthetic and Reconstructive Surgery (AMCPE); ¶Western Mexican Association of Plastic, Esthetic and Reconstructive Surgery (SCPERO); and ||Jalisco College of Plastic Surgeons.

Presented at the XXXIX annual meeting of the Mexican Association of Plastic Reconstructive and Anesthetic Surgery in May 2008 On Acapulco Gro, México. Reprints: Lázaro Cárdenas-Camarena, MD, Neoplastic, Centro Médico Puerta de Hierro, Boulevard Puerta De Hierro 5150. Edificio C Int. 403, Zapopan, Jalisco, México. E-mail: pllassurg@mail.udg.mx.

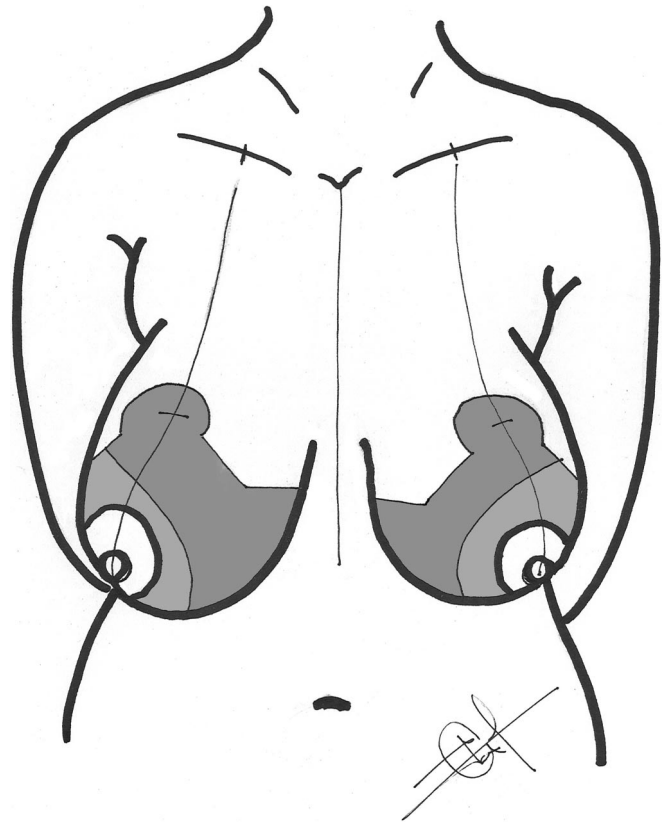
Copyright © 2009 by Lippincott Williams & Wilkins  
ISSN: 0148-7043/09/6303-0001

DOI: 10.1097/SAP.0b013e31818d45c2

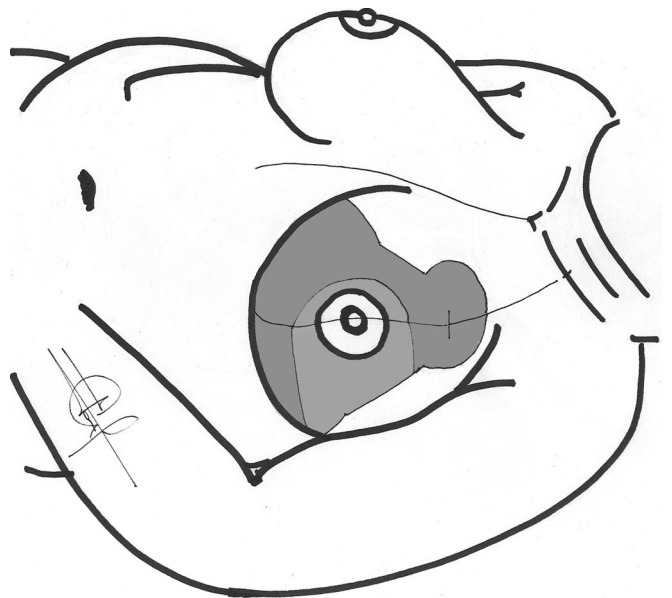
sensitivity was the same or different in the NAC. Altered sensitivity was considered as minimal, moderate, or severe. Results with a moderate or severe condition were considered and reported as an alteration in NAC sensitivity. Functionality of the gland was assessed only during the first 8 years of performing this technique and consisted of determining how many patients required breast-feeding and how many were able to do so with no problem.

### Design of the Surgical Technique

Patients are marked before the surgical procedure. All marking is done with the patient seated facing the surgeon. To perform the marking, it is necessary to determine 5 basic points: the suprasternal notch, the submammary crease, the anterior axillary line, the midsternal line, and the midclavicular line. This last line corresponds to the central meridian of the breast. This meridian usually begins in the clavicle at 7.5 cm from the suprasternal notch and passes through the center of the NAC, but it may be displaced more laterally or medially, in cases when a more lateral or medial migration of the NAC is desired. With these points marked, the center position of the new NAC is established. We determine this position between 20 and 22 cm from the suprasternal notch, taking into account the patient's height and confirming it by the forward projection of the submammary crease.<sup>3</sup> Having determined the center of the new NAC, we use a template similar to Wise's pattern to establish the total design of the technique. This template, made in a semi rigid plastic, consists of an oval 6 cm wide by 4 cm high, which corresponds to the diameter of the new NAC. The center of this oval is located at the point where the position of the new NAC was determined. The difference between the height and width of the new NAC in the design is due to the fact that at the time of closing the lateral branches, the shape is compensated to remain round. The lateral branches of the design spread out from the center of this oval. These lateral branches will measure from 5 to 7 cm in length from the outer edge of the new areola. Their length will vary according to the size of the new breast. The length of these branches will comprise the size of the vertical scar of the breast after the surgery. The bigger the new breast, the longer this scar will be, and vice versa. The lateral branches may vary in their angle of amplitude when they leave the new NAC. Their variation fluctuates between 90 and 120 degree. The smaller the angle of divergence of the branches, the less tissue will be removed, while if the branches have amplitude of 120 degree or more, the tissue to be eliminated will be bigger. Therefore, the more amplitude there is between the lateral branches, the smaller the new breast will be. The ends of these branches will join another line at the new submammary crease, which is placed between 0.5 cm and 1 cm above the original one. The lateral portion of this union should not go beyond the anterior axillary line and its medial portion should be located at 3 cm inside the midsternal line. This is to keep the scar on the submammary crease in its medial or lateral portion. Once the design of the cuts is drawn, the position of the pedicle is marked. It is simpler to do this marking with the patient lying down. The pedicle originates in the lateral branch of the new breast design that is already marked. It is 7 to 8 cm wide, and the thickness includes all the mammary thickness up to the chest wall. The length of the pedicle extends 3 to 4 cm beyond the NAC. It is important to situate the pedicle in a completely lateral position to avoid torsion when being rotated toward its definitive position. This is one of the most important changes that we made from our original technique, avoiding blood-supply compromising secondary to torsion of the pedicle. When the patient stands up, the pedicle is seen as superolateral. With this design, preserving the integrity of the pedicle up to the chest wall, deep innervation of the NAC is maintained, since the nerves coming from the lateral portion are not damaged or sectioned. The complete design of the technique is shown in Figures 1 and 2.




**FIGURE 1.** We can see the design of the technique. The pedicle originates in the lateral branch of the new breast design. It is 7 to 8 cm wide, and the length of the pedicle extends 3 to 4 cm beyond the NAC.



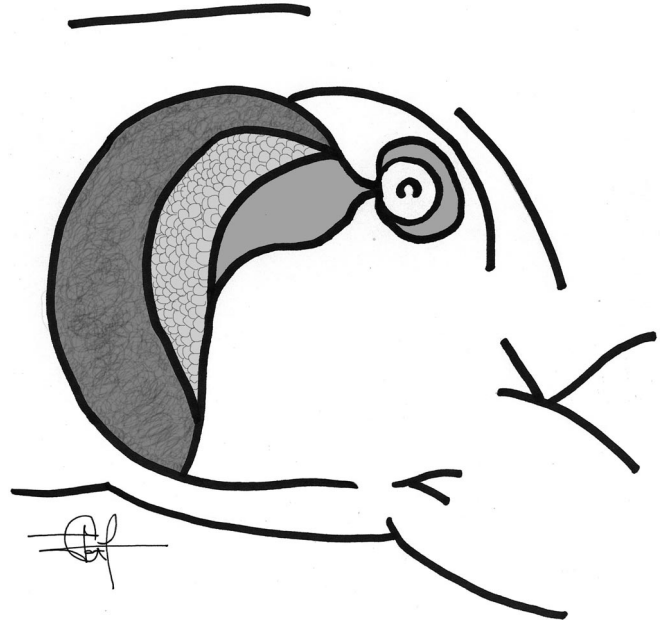
**FIGURE 2.** It is important to situate the pedicle in a completely lateral position to avoid torsion when being rotated toward its definitive position, and to maintain all the neurovascular advantages of the pedicle. The design of the pedicle is made with the patient lying down. When the patient stands up, the pedicle is seen as superolateral.

### Performing the Surgical Technique

Surgery is performed with general anesthesia or epidural block. The breast is infiltrated with a preparation consisting of 300 mL of 0.9% saline solution and 1 mL of adrenaline. If general anesthesia is used, 50 mL of 2% simple lidocaine are added, to decrease the consumption of inhaled anesthetic. If the amount to be infiltrated is larger, because of the breast size, twice the amount of solution to be infiltrated can be prepared, maintaining the same preparation. The first step consists of deepithelialization of the area corresponding to the vascular pedicle, leaving the new NAC's diameter of approximately 4 cm. The entire area outside the vascular pedicle, but inside the lines of the design, is completely extirpated (Fig. 3). Thus, the size of the new breast is going to be determined exclusively by the size and thickness of the vascular pedicle. It is important to emphasize that the cuts made to extirpate the breast tissue are made completely perpendicular to the chest wall, being absolutely straight without any undermining, keeping the pedicle attached to the chest wall. Even though the pedicle is attached to the chest wall, it can be easily moved and rotated, since the movement is oblique and tilting the tissue, which causes no significant problem. Making all the cuts perpendicular to the chest wall and with no undermining, avoids thinning the pedicle or the lateral flaps of the new breast, and maintains the vascular supply and nerves in the pedicle. Once the tissue is removed, the pedicle is rotated toward the new NAC position, which is usually achieved without any problem or tension (Fig. 4). A final basic point in the technique is the conification and fixation of the breast tissue to shape the new breast. This procedure is done using nonabsorbable 1 and 2-0 prolene sutures to fix the pedicle to the medial portion of the pectoral muscle, giving it the definitive shape that is desired. This avoids using the skin to create the breast conification and fully minimizes wound dehiscence. Closing is done by planes, using 2-0, 3-0, and 4-0 absorbable monofilament Monocryl sutures. Drainage is left at



**FIGURE 3.** In the surgical procedure, all the area outside the vascular pedicle, but inside the lines of the design, is completely extirpated, and all the cuts must be made perpendicular to the chest wall, maintaining attachment to the pectoral fascia.



**FIGURE 4.** The pedicle has been rotated toward the new NAC position, which is usually achieved without any problem or tension. The pedicle is going to create the size and shape of the new breast.

negative pressure for 24 to 48 hours, and a breast support is indicated for 3 to 4 weeks.

### RESULTS

Between April 1992 and March 2008, we have used this technique on 702 breasts of 356 patients. All patients presented mammary hypertrophy, and the NAC required a migration of 5 to 16 cm (mean: 9.2 cm), resecting 300 to 1380 g (average: 660 g) of each breast. Patients were between 16 and 63 years of age (average: 37 years). All 356 patients were followed up for 6 months; thereafter, follow-up was more irregular, continuing for more than 10 years in many patients, although not in all. Average follow-up in the total operated patients was 6 years and 7 months. There were major and minor complications, the principal minor complication being wound dehiscence at the union of the vertical and horizontal incisions. This dehiscence was counted as a complication when the open area was more than 2 cm<sup>2</sup> and it took over 3 weeks to close by second intention. This problem was present in 42 cases (5.9%), and there was no need to close the area surgically in any of the cases. It is important to mention that the incidence of this complication was greater when shaping and conification of the new breast was performed solely with the cutaneous brassiere. After we began fixing the gland to the chest wall or performing conification of the breast with sutures, the incidence of this complication decreased considerably. Before performing these maneuvers, our dehiscence rate in this area was about 10%; with plication and fixation of the gland, our rate has decreased to less than 4%. Hypertrophic scars and keloids occurred in 22 and 4 breasts, respectively (3.1% and 0.5%, respectively). Six with hypertrophic scars and one with a keloidal scar required corrective surgery; the rest progressed satisfactorily with pressotherapy and intralesional corticoids. Surgical corrections of the hypertrophic and keloidal scars were performed jointly with intralesional corticoids, starting 3 weeks after the surgical correction, and the evolution was satisfactory. Hyperpigmented scarring occurred in 28 breasts (3.9%); all were treated with hydroquinone-

based hyperpigmentation creams, and most patients reported significant aesthetic improvement in the scar color. Fat necrosis was evident in 27 breasts (3.8%) and was also most frequent in the first years after performing this surgical technique because of the tension that occurred on the stitches used for breast conification. All these patients progressed conservatively with antibiotics and anti-inflammatories. One patient presented a fat cyst that had to be drained by puncturing. Only 16 breasts (2.27%), from a like number of patients, ie, 1 breast in each patient, were reported with partial alteration of sensitivity 3 months following surgery. Lactation ability was assessed during the first 8 years after using this technique. During these 8 years, it was found that 42 patients (23%) needed to breast-feed after surgery, and only 3 (3%) had congestion problems and breast pain, causing them to discontinue breast-feeding. The remaining 39 (20%) had no lactation problems. These findings show us no breast-feeding problems in 93% of the operated patients, with only 7% of them presenting problems necessitating discontinuation of breast-feeding.

Nine cases (1.28%) of NAC necrosis occurred, 7 of which (0.99%) were partial and 2 were total (0.28%). Partial necrosis was considered to be that in which there was 20% skin loss, but not total loss, and in which scarring left alterations in the NAC. Partial necrosis occurred in all 7 patients in whom breast tissue resection was greater than 800 g and NAC migration was over 10 cm. Five of these cases occurred in the first 50 breasts that were operated on with the technique, where the pedicle was located in a very superior position, in accordance with Skoog's original description, and torsion to move it into position was significant. The 2 cases of total necrosis occurred unilaterally in overweight patients in whom 1000 and 1150 g of breast tissue were resected, with migration of 12 and 14.5 cm, respectively. The first was a smoker of over 20 cigarettes a day until 3 weeks before surgery. The second patient, 55 years old, was a passive smoker and she had no alteration until 5 days following surgery, when she presented sudden NAC congestion and total NAC necrosis at 10 days. In both cases, it was necessary to do a secondary surgery and reconstruction of the NAC. The summary of complications is shown in Table 1.

There were no problems with infection, and the degree of satisfaction reported by the patient with the result obtained was 94%. Patients operated on with this technique are shown in Figures 5 to 8.

**DISCUSSION**

In the 1970s, Skoog designed a reduction mammoplasty technique using a lateral dermal pedicle.<sup>4</sup> Skoog's vascular support was based on anatomic descriptions done by Cooper in 1840<sup>5</sup> and confirmed by Marcus in 1934,<sup>6</sup> where vascularity of the breast is described with significant lateral irrigation. Initially, Skoog designed his pedicle solely with a thin dermal component, but upon observing venous congestion in some of the cases, he decided to make it

thicker at the proximal region, but never with a dermoglandular component. Also, Skoog was against including the pedicle with a glandular component because, if there was vascular compromise, the lesion of the entire pedicle would considerably damage the overall structure of the new breast, and manipulation of such a thick pedicle made it more difficult to achieve an adequate aesthetic result.<sup>4</sup>

The principal advantage of the lateral pedicle described by Skoog is the vascular supply. Recent studies by O'Dey et al<sup>7</sup> found that the most constant and thickest branches, which provide irrigation to the breast and the NAC, come from the external mammary, or lateral thoracic artery. This artery was found in 100% of the cadaver dissections that they performed, and the internal mammary artery showed irrigation of the NAC in 86% of their dissections. These findings had already been described by Nakajima et al<sup>8</sup> several years before. However, significant in these descriptions is the assertion that not only is the anatomic location of the pedicle important, but so too is its thickness. They found that very thin pedicles such as dermal pedicles sacrifice many important vessels, so the thickness of a pedicle should also be taken into account when choosing the surgical technique. Thus, a dermoglandular pedicle preserves greater vascularity than a dermal pedicle. The technique that we have described is based on Skoog's basic design; however, we have tried to take full advantage of the vascular contribution by leaving the pedicle with a glandular component to fully respect the anatomy of the lateral thoracic artery. We emphasize that this type of pedicle also receives smaller supplementary vessels from the anterior and posterior branches of the intercostal arteries, as well as from the upper thoracic, thoracoacromial, and superficial thoracic arteries.<sup>7</sup>

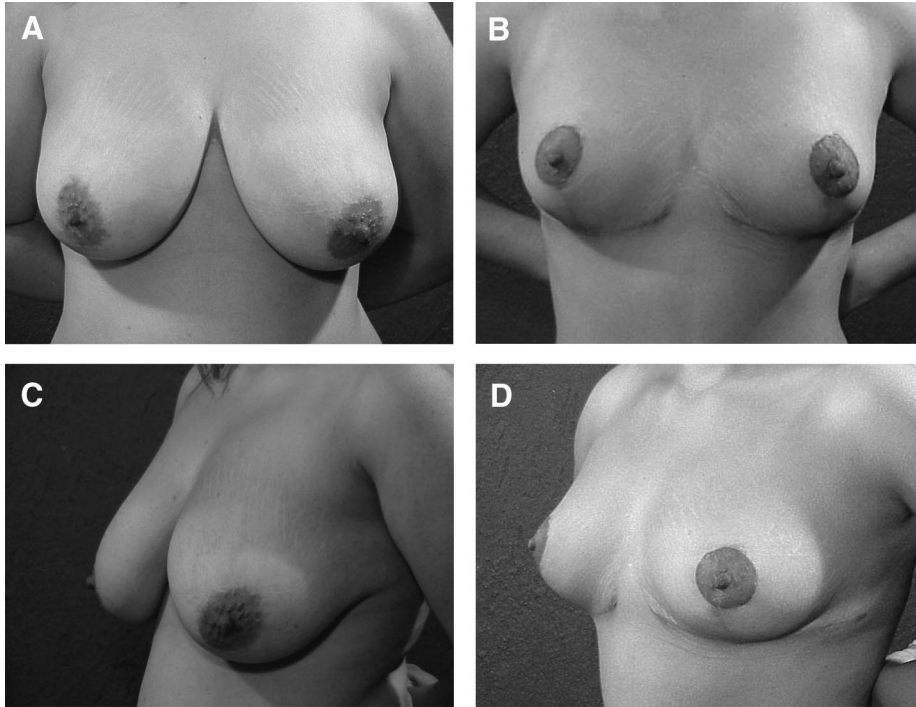
Sensitivity and functionality of the NAC in a dermal flap are affected significantly. The fourth intercostal nerve is the most important in providing sensitivity to the NAC<sup>9-16</sup>; however, the cutaneous branches of the third and fifth intercostal nerves also contribute sensitivity.<sup>17</sup> Schlenz et al<sup>13</sup> found in an anatomic study of cadaver dissection that the most constant and significant nerve that provides NAC sensitivity is the lateral cutaneous branch of the fourth intercostal nerve, which was found in 93% of cases. They also found that the anterior cutaneous branch of the third and fourth intercostal nerves was present in 57% of their dissections. Therefore, based on these dissections, the lateral nerves are the most constant and the ones that provide the greatest sensitivity to the NAC. However, one must take into consideration that not only is the location of the pedicle fundamental in providing sensitivity to the NAC in reduction mammoplasty, but also the thickness of the pedicle.<sup>13</sup> Ninety-three percent of the cutaneous branches that come from the lateral nerves are deep branches that emerge through the fascia of the pectoral muscle, and only 7% have a superficial trajectory. Therefore, by maintaining the thickness of the breast, integrity is fully maintained in these nerves, which are 5 times thicker than other nerves that reach the NAC.<sup>13</sup> These data about NAC's sensitivity and the nerve routes in the superficial and deep breast's areas had already been pointed out in previous studies.<sup>10,11,15,16</sup> Therefore, it has been shown that sensitivity achieved in the NAC when doing reduction mammoplasty depends more on how cuts are made on the breast and the technique employed than on the amount of tissue resected.<sup>13,18</sup> Techniques that use a dermal or superior pedicle, where the base of the breast is resected or cut, greatly affect sensitivity.<sup>18</sup> Skoog, in his original description,<sup>4</sup> pointed out that NAC sensitivity was affected in most of his patients, although it was nearly always recovered after 1 year. The design of our technique, using the full thickness of the breast within the pedicle, has allowed us to eliminate this problem completely, because we fully preserve the integrity of the most important nerves that sensitize the NAC.

On the other hand, when a dermal pedicle is used, the galactophorous ducts are inevitably cut and separated from the breast. There-

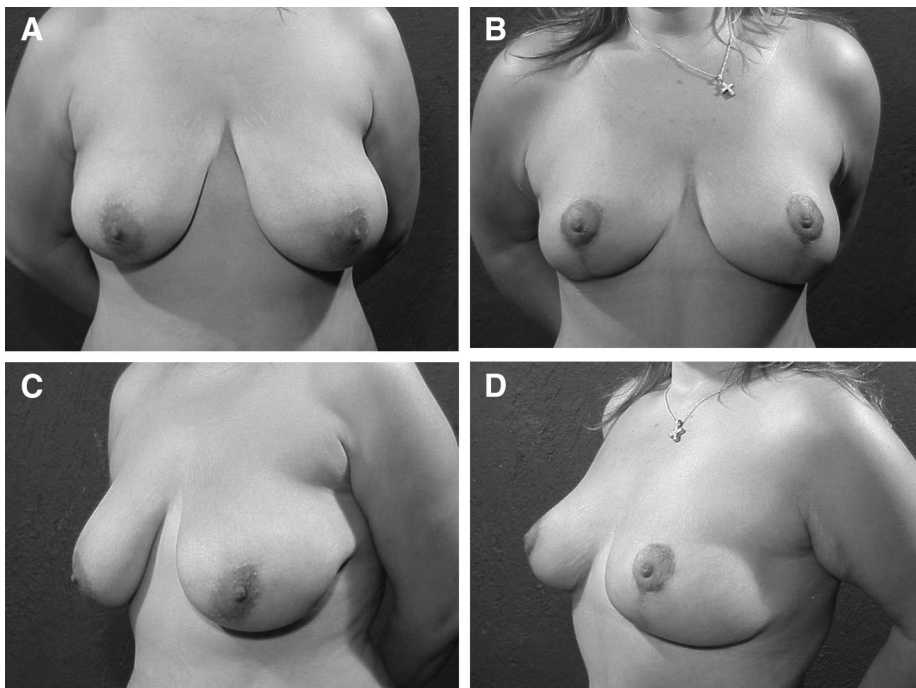
**TABLE 1.** Number and Percentage of Complications

Complication	Number and Percentage*
Wound dehiscence	42 (5.9%)
Scar hyperpigmentation	28 (3.9%)
Fat necrosis	27 (3.8%)
Hypertrophic scarring	22 (3.1%)
Alterations in sensitivity	16 (2.27%)
Keloid scarring	4 (0.5%)
Partial NAC necrosis	7 (0.99%)
Total NAC necrosis	2 (0.28%)

\*The percent indicated is according to the total number of breast operated.



**FIGURE 5.** Patient 1. Twenty-four years old, shown before and 6 months after surgery. No prior pregnancies. Migration of the NAC was 7 cm and breast tissue removed was 600 g from each breast. Her skin quality was very good, so it helps to maintain a very good post-operative result. The scars in the submammary crease are still improving. Front view, presurgery (A) and postsurgery (B); and three-quarters view, presurgery (C) and postsurgery (D).

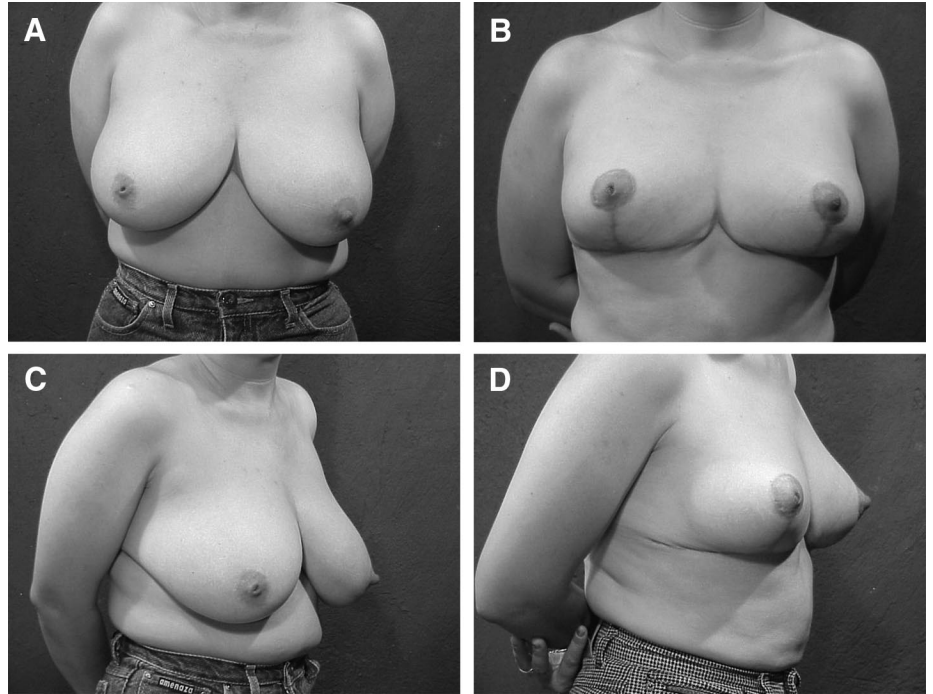


**FIGURE 6.** Patient 2. She shown before surgery and 8 months post-surgery. She is 31 years old, and her skin quality is also good. She had no prior pregnancies 425 g were removed from each breast, and the NAC was migrated 7 cm. Her skin quality allows maintaining the conical shape. This patient presented mammary asymmetry and reduced medial volume preoperatively, a situation that improved significantly with surgery. Front view, presurgery (A) and postsurgery (B); and three-quarters view, presurgery (C) and postsurgery (D).

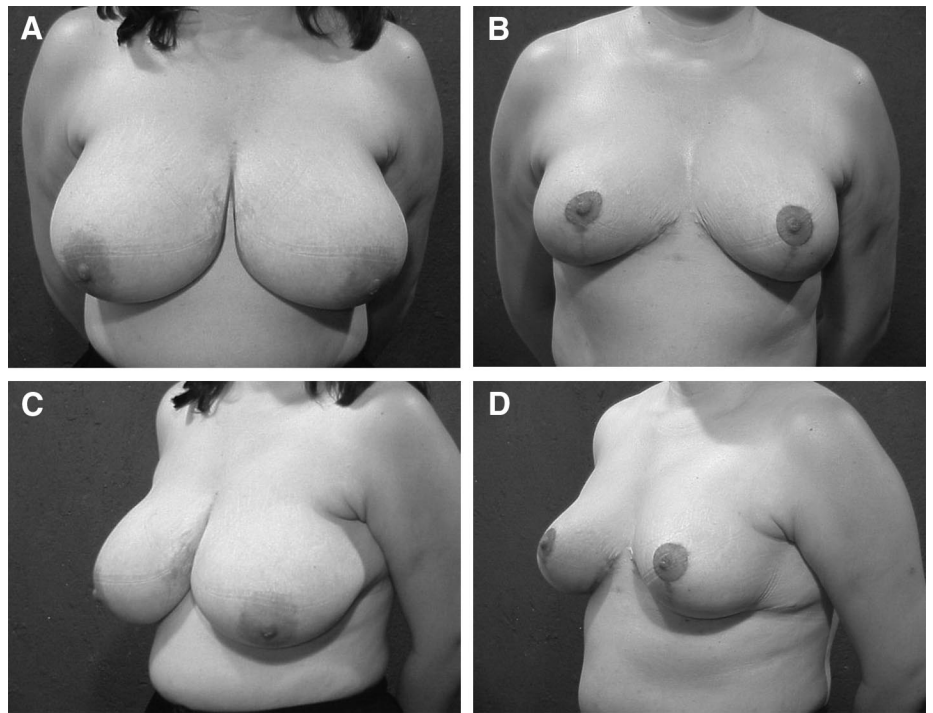
fore, the integrity and functionality of the main function of the breast is damaged. It is difficult to recover this function in most cases.<sup>4</sup> Avoiding sectioning the galactophorous ducts by using a glandular pedicle has allowed us to preserve this function fully. This condition we were able to determinate it during the first years of using this technique, where most of our patients had no problem with breast-feeding. Therefore, with any technique, if a dermal pedicle is used, whatever the location of the pedicle, the galactophorous ducts are sectioned and inevitably functionality is always compromised. Likewise, separation of the pedi-

cle from its connection to the gland will inevitably damage and section deep nerve connections, affecting NAC sensitivity. For this reason, we feel that leaving a dermoglandular pedicle provides anatomically obvious benefits and is superior to any dermal pedicle. Even more so, if the dermoglandular pedicle is strategically located, like in a superolateral position, we will take full advantage of the vascular and nerve benefits that different authors reports.<sup>5-8,13,18</sup>

One of the most important details in performing this surgical technique is proper placement of the vascular pedicle. In our first



**FIGURE 7.** Patient 3. This patient is 42 years old, had 2 previous pregnancies, and presented 6 months after surgery. Her breast asymmetry is evident 750 and 850 g were removed from the right and left breast respectively, and the NAC was migrated 8 and 10 cm, respectively. Her postoperative symmetry and results are good; nevertheless, the breast base was very wide, and this caused the postoperative breast base wide. Front view, presurgery (A) and postsurgery (B); and three-quarters view, presurgery (C) and postsurgery (D).



**FIGURE 8.** Patient 4. This 48-year-old patient, with 3 previous pregnancies, had very fatty breast tissue and poor skin quality. So at 8 months after surgery it does not have ideal upper pole fullness. Her NAC migration was 12 cm, and her breast tissue removal was 900 and 950 g from each breast. She needed major fat reduction in the lateral axillary portion, but it was left for a second time with liposuction, to avoid damaging the vascular pedicle. Front view, presurgery (A) and postsurgery (B); and three-quarters view, presurgery (C) and postsurgery (D).

cases, we placed it very high. This design followed Skoog's original design,<sup>4</sup> where the beginning of the pedicle was in the highest portion of the lateral branch of the drawing. However, including a glandular component in our design caused torsion of the pedicle when taking it to its definitive position. This torsion produced congestion in it. This congestion does not occur in a dermal pedicle because a thin pedicle has a broader NAC's rotation than a thick one. For that reason, in our first cases, we had significant congestion with

suffering and superficial necrosis of the NAC. We were obliged to modify the location of the pedicle and place it in a position that was more lateral than superior. With this change, rotation of the pedicle ceased being a drawback, and the problem of congestion from torsion disappeared. To achieve this result, we must have the patient lying down when drawing the pedicle, to place it completely lateral to the NAC. If the patient gets up, we will be able to see by the descend of breast that the real position of the pedicle is superolateral,

and not completely lateral. This same basic fact is why we only indicate this technique in patients whose NAC migration is greater than 5 cm, since lesser displacements would produce NAC congestion by requiring a very forced rotation to take it to its new position. This congestion is due to the fact that the pedicle includes dermoglandular tissue adhered to the chest wall. This adherence, which is mandatory to preserve the advantages of this technique, allows pedicles whose migrations are greater than 6 cm to be easily moved. This is because the very looseness of the tissue favors it, since the tissue is displaced by moving it obliquely. However, pedicles whose migration is less than 5 cm requires torsion to achieve the rotation, and their movement is forced. In migrations of less than 5 cm, we use a superior pedicle. Rotation can be more difficult in patients whose NAC is more lateralized than usual, since in these cases, the length of the pedicle is shorter, although we have had no problems performing it even in these cases. We have used the technique in migrations of up to 16 cm with no problem whatsoever.

Because the pedicle is located in the lateral portion of the breast, when there is too much volume in that area, the lateral portion may remain voluminous. In these cases, the volume can be decreased by limiting the thickness of the pedicle to the described 7 cm. In more severe cases, if necessary, extraction of fat by liposuction in the lateral portion is recommended, but this should always be done in another surgical time to avoid producing vascular damage of the vascular pedicle.

Like any technique, it is not exempt from complications. Fortunately, the percentage of complications, both minor and major, is very low, and all of them have an explanation and therefore, a way to minimize them fully. Probably the major disadvantage of this technique is the size of the scars, which is a disadvantage of a large number of techniques. However, these scars are the most used in performing reduction mammoplasty in the United States<sup>19</sup>; techniques with big scars leave patients more satisfied because the results in the breast are aesthetically more satisfactory than the techniques that leave reduced scarring.<sup>19</sup> They also require fewer revisions and corrections. The techniques with limited incisions, such as periareolar<sup>20,21</sup> and vertical techniques,<sup>17,22–25</sup> are reported by surgeons as not very satisfactory to perform because of their complexity, because they have a long learning curve, and because pleasing results are not easy to achieve.<sup>19</sup> Like previous reports,<sup>26,27</sup> our complications, in number and severity, have occurred in patients in whom a significant amount of breast tissue has been resected, so in these types of cases, we must act more cautiously and inform the patient of this probability. As with any reduction mammoplasty, smoking is one of our worst enemies. The 2 patients who had total NAC necrosis were significant smokers, one active and the other, passive. Fortunately, this technique has provided satisfactory results in more than 90% of our patients.

We feel that this technique offers big advantages, taking full advantage of the characteristics that should be looked for when performing any surgical technique. We believe that this pedicle is seldom used because of the popularity that other techniques have gained over the years and lack of knowledge of the great advantages that this pedicle provides. It is a simple technique to design and easy to carry out. There is no complexity in performing it. The aesthetic results are easily obtained and are reproducible. Also, because of its design and characteristics, it fully protects the factors to be careful about when performing reduction mammoplasty: vascularity, sensitivity, and functionality. Superolateral placement involves the most important vessels and nerves for preserving NAC vascularity and sensitivity, and the glandular component safeguards deep nerves and galactophorous ducts. For this reason, reduction mammoplasty using

a superolateral dermoglandular pedicle is among the most recommendable and the safest for the treatment of mammary hypertrophy and gigantomasty.

## REFERENCES

- Goldwyn RM. *Reduction Mammoplasty*. Boston/Toronto/Canada: Little, Brown and Company; 1990.
- Cárdenas-Camarena L, Vergara R. Reduction mammoplasty with superior-lateral dermoglandular pedicle: another alternative. *Plast Reconstr Surg*. 2001; 107:693–699.
- Gulyás G. Marking the position of the nipple-areola complex for mastopexy and breast reduction surgery. *Plast Reconstr Surg*. 2004;113:2085–2090.
- Skoog T. *Plastic Surgery. New Methods and Refinements*. Stockholm, Sweden: Almqvist & Wiksell; 1974.
- Cooper AP. *On the Anatomy of the Breast*. London: Longman, Orme, Green, Brown and Longmans; 1840.
- Marcus GH. Untersuchungen über die arterielle Blutversorgung der Mamilla. *Arc Klin Chir*. 1934;179:361–369.
- O'Dey DM, Prescher A, Pallua N. Vascular reliability of nipple-areola complex-bearing pedicles: an anatomical microdissection study. *Plast Reconstr Surg*. 2007;119:1167–1177.
- Nakajima H, Imanishi N, Aiso S. Arterial anatomy of the nipple-areola complex. *Plast Reconstr Surg*. 1995;96:843–845.
- Courtiss EH, Goldwyn RM. Breast sensation before and after plastic surgery. *Plast Reconstr Surg*. 1976;58:1–13.
- Craig RD, Sykes PA. Nipple sensitivity following reduction mammoplasty. *Br J Plast Surg*. 1970;23:165–172.
- Gonzalez F, Brown FE, Gold WE, et al. Preoperative and postoperative nipple-areola sensibility in patients undergoing reduction mammoplasty. *Plast Reconstr Surg*. 1993;92:809–814.
- Mofid MM, Dellon AL, Elias JJ, et al. Quantitation of breast sensibility following reduction mammoplasty: a comparison of inferior and medial pedicle techniques. *Plast Reconstr Surg*. 2002;109:2283–2288.
- Schlenz I, Kuzbari R, Gruber H, et al. The sensitivity of the nipple-areola complex: an anatomic study. *Plast Reconstr Surg*. 2000;105:905–909.
- Serletti JM, Reading G, Caldwell E, et al. Long-term patient satisfaction following reduction mammoplasty. *Ann Plast Surg*. 1992;28:363.
- Slezak S, Dellon AL. Quantitation of sensibility in gigantomastia and alteration following reduction mammoplasty. *Plast Reconstr Surg*. 1993;91:1265–1269.
- Wechselberger G, Stoss S, Schoeller T, et al. An analysis of breast sensation following inferior pedicle mammoplasty and the effect of the volume of the resected tissue. *Aesthetic Plast Surg*. 2001;25:443–446.
- Hall-Findlay EJ. A simplified vertical reduction mammoplasty: shortening the learning curve. *Plast Reconstr Surg*. 1999;104:748–759.
- Schlenz I, Rigel S, Schemper M, et al. Alteration of nipple and areola sensitivity by reduction mammoplasty: a prospective comparison of five techniques. *Plast Reconstr Surg*. 2005;115:743–751.
- Rohrich RJ, Gosman AA, Brown SA, et al. Current preferences for breast reduction techniques: a survey of board-certified plastic surgeons 2002. *Plast Reconstr Surg*. 2004;114:1724–1733.
- Benelli L. A new periareolar mammoplasty: the round block technique. *Aesthetic Plast Surg*. 1990;14:93–100.
- Sampaio-Goes JC. Periareolar mammoplasty double skin technique. *Breast Dis*. 1991;4:111.
- Lassus C. A technique for breast reduction. *Int Surg*. 1970;53:69–72.
- LeJour M, Abboud M, Decléty A, et al. Réduction des cicatrices de plâtré mammaire de l'ancrecourte à la verticale. *Ann Chir Plast Esthet*. 1990;35: 369.
- Leone MS, Franchelli S, Berrino P, et al. Vertical mammoplasty: a personal approach. *Aesthetic Plast Surg*. 1997;21:356–361.
- Renault P. Reduction mammoplasty by the "B" technique. *Plast Reconstr Surg*. 1974;53:19.
- Cunningham BL, Gear AJL, Kerrigan CL, et al. Analysis of breast reduction complications derived from the BRAVO study. *Plast Reconstr Surg*. 2005; 115:1597–1604.
- Strömbeck JO. Report of a new technique based on the two pedicle procedure. *Br J Plast Surg*. 1960;13:79–90.

## AUTHOR QUERIES

### **AUTHOR PLEASE ANSWER ALL QUERIES**

1

AQ5—Please provide short running head.

AQ4—Please provide the location and department/division name for the last affiliation.

AQ1—Please check figures carefully. Is the legend for each photo correct?

AQ3—Please note that Figures 5–20 have been changed to Figures 5–8, each with parts A-D.

AQ2—Please note that references have been renumbered to ensure sequential order.

---