

Various Surgical Techniques for Improving Body Contour

Lázaro Cárdenas-Camarena, M.D.

Jalisco, México

Abstract. Body contouring surgery is the most frequently performed aesthetic surgical procedure. Multiple and varied options exist for obtaining an adequate body contour, and most surgeries address the thoracoabdominal region. Because the success of a surgery depends greatly on the selection of the proper surgical procedure, this article presents an approach for selecting the best surgical option based on the characteristics of each patient. Considering this, surgeons approach a contour problem with two options: to modify the content or to modify the container. These options include five basic surgical procedures: pexia, dermolipectomy, liposuction, fat infiltration, and implant placement. Each patient requires a different technique and many need several procedures during the same surgical session to obtain the best results. Likewise, each procedure should be undertaken according to precise indications, depending on the aesthetic problem of the patient and the individual characteristics of the treated area. It is for this reason that the most important factors to be considered should be analyzed to determine the best surgical procedure and the combination of surgical procedures that will improve the thoracoabdominal contour for the same patient.

Key words: Abdominoplasty—Body contour—Gluteoplasty—Liposuction

Body contouring applies to multiple areas of the body because practically any area of the body may be improved through surgical intervention [3,27]. For that reason, body contour surgery is the most common aesthetic surgery practiced in the United States, and very probably worldwide [29].

When a surgeon speaks of body contour surgery, he generally is referring to the middle third of the body including the abdomen, flanks, trochanteric regions, lumbar region, and gluteal region. However, the body contours also may be improved significantly through surgery in the mammary region [4,14], thighs [21], and calves [23]. Because of this, it is important to note that although body contouring may encompass the entire body, its reference in this report specifically indicates the middle third of the body. This region includes the area between the inframammary line and the gluteal region including the abdomen, flanks, trochanteric region, lumbar region, and gluteal region.

Surgical Techniques

Body contour improvement may be visualized according to the following scheme shown in Fig. 1. According to the scheme, two basic procedures are used to improve body contour: container modification and content modification. Container modification is focused specifically toward reduction. This reduction implies pexia procedures of ptotic tissues [19,20,30] and/or the elimination of fatty tissue, loose tissue, or both with dermolipectomy [2,24]. For some patients, who have significant tissue excess, a dermolipectomy needs to be performed around the body circumference for improvement throughout the area [27,30]. We have performed 22 belt dermolipectomies, with dehiscence of the wound in the posterior region of five patients. If we undermine only the tissue to be eliminated, the complications are very uncommon. These procedures may be performed either separately or in combination, according to the indications for each procedure [7,12], and for each particular case.

Whereas container modification includes only reduction procedures, content modification may include either reduction or augmentation procedures.

Correspondence to L. Cárdenas-Camarena, M.D. Centro Médico Puerta de Hierro, Boulevard Puerta De Hierro 5150, Edificio C Int. 403, Zapopan, Jalisco, México; *email:* plassurg@mail.udg.mx

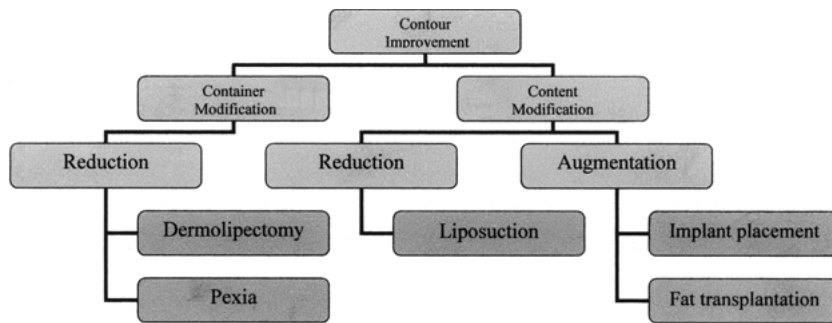


Fig. 1. Diagram showing the means for achieving improved body contouring.

Content augmentation of a specific body region may be achieved by different means. The use of alloplastic implants is one of the most common options [31,32]. Another alternative with excellent results involves the use of fat grafting [8,15]. The most common aesthetic content reduction procedure is liposuction [16]. Similar to the procedures for container modification, these procedures may be combined according to each individual case [8].

Summarizing the basic procedures previously mentioned, the five surgical techniques that can be used for body contour improvement are pexia, dermolipectomy, liposuction, fat infiltration, and implant placement. The combination of container reduction procedures such as dermolipectomy with a content augmentation procedure using fat infiltration and/or a content reducing procedure, such as liposuction, constitute lipoplasty, and the terminology must be followed. A judicious choice and a combination of these techniques will determine the success or failure of the surgical procedure. Therefore, it is of greatest importance to evaluate the patient adequately for selection of the correct surgical combination.

Liposuction

Liposuction is the most frequently performed aesthetic surgery [29]. We have used this technique for 1,226 patients, with a complication rate similar to that described in the medical literature. In this series, we included only female patients. For 466 (38%) of the 1,226 patients, lipoaspiration of 5,000 ml or more was the only surgical procedure. For 150 patients (12.2%), lipoaspiration of 500 to 4,999 ml was the only surgical procedure performed. For 404 patients (32.9%), thoracoabdominal circumferential lipoaspiration was performed in combination with abdominoplasty. For 206 patients (16.8%), lipoaspiration was performed together with an aesthetic surgery other than abdominoplasty.

There were no complications for 962 patients (80%). Minor complications were noted for 238 patients (19.4%). The rate of minor complications was similar in all the groups, with no statistically significant differences.

Six patients (0.48%) had major complications. Four of these patients underwent abdominoplasty in conjunction with liposuction, so they are included in the abdominoplasty and liposuction section. One of the major liposuction complications, fat embolism syndrome, occurred in a patient who had undergone gluteal lipoinjection. The remaining patient experienced a cutaneous necrosis. Both problems were resolved satisfactorily.

Of the 238 patients with minor complications, 78 (6.3%) presented with palpable irregularities, and 52 (4.3%) had visible irregularities. Of these, 44 (3.5%) were minor irregularities, whereas 12 (0.9%) were determined to be overcorrections. Seromas developed in 56 patients (4.5%), and had to be drained on at least one occasion. Hyperpigmentation in the lipoaspirated region or the incision used for lipoaspiration was experienced by 47 patients (3.9%). Four (0.32%) patients experienced superficial cutaneous compromise, whereas one patient (0.08%) presented with a local infection in a small area of the lumbar region. The volume of aspirated material ranged from 500 to 22,200 ml (median, 6,230 ml).

The basic indication for liposuction is an excessive amount of adipose tissue and good skin quality that permits adequate skin retraction and an excellent outcome. Our surgical technique has been described in previous works [9]. Marking, performed with the patient in the standing position, is performed in a circumferential thoracoabdominal fashion to obtain the best contour. The procedure is performed with a peridural block to achieve regional anesthesia, and to offer postoperative analgesia. The patient is placed exclusively in two positions: the ventral decubital position initially and the dorsal decubital position finally.

Liposuction is performed using the tumescent technique with infiltration using an isotonic solution of 0.9% saline and 1 ampule of adrenaline. Because epidural anesthesia is used, lidocaine in the tumescent solutions is not required. Lidocaine is used only in one or two solutions when anesthesia is not attained with a peridural block (e.g., upper dorsum, arms). We do not use internal or external ultrasound because our studies have not demonstrated that it has an advantage over the classic tumescent technique [5,6].

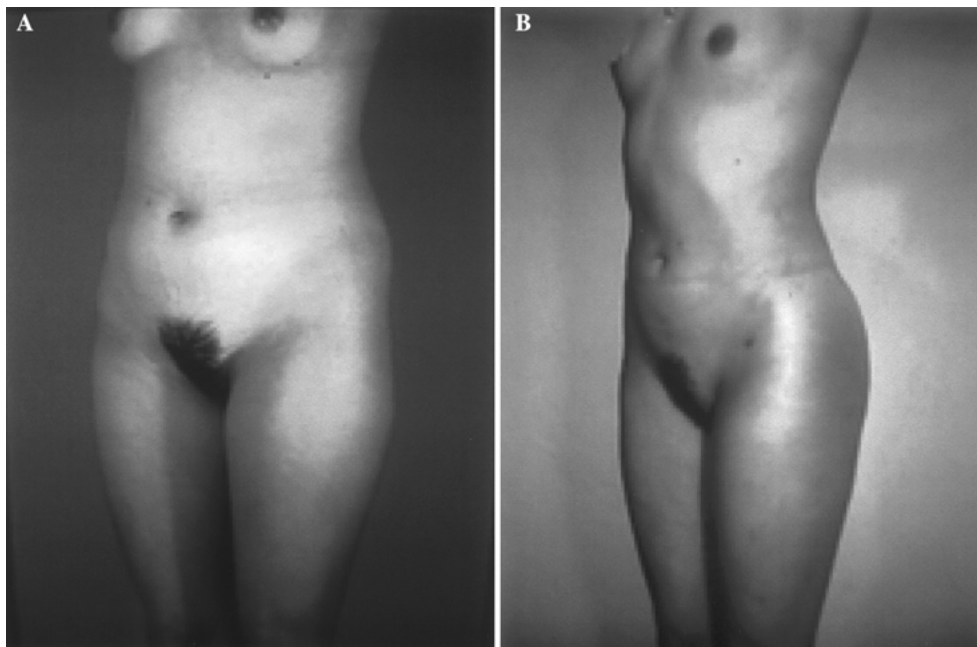


Fig. 2. A 23-year-old woman underwent body contour improvement solely through liposuction. The patient's skin is excellent. Adequate cutaneous retraction provided a good result.

Liposuction is performed by two plastic surgeons simultaneously, coordinated by the primary surgeon, with a significant saving of surgical time. Only 5-, 4-, and 3-mm cannulas are used, with the latter two used most commonly. Flap thickness is determined by the pinching maneuver and by observing the regularity of the flap when the cannula is lifted. A soft open silicone drain is always left in place both anteriorly and posteriorly for a period of 5 days. We use compressive dressings and postoperative girdles for approximately 6 weeks, therapeutic postoperative ultrasound after day 5 every third day for 1 month, and 15 to 20 sessions of endermology after 1 month. The results obtained exclusively with the use of liposuction may be seen in Figs. 2 and 3.

Abdominoplasty With Liposuction

The main indication for combined abdominoplasty and liposuction is thoracoabdominal lipodystrophy, but with an excessive amount of abdominal flaccidity. This flaccidity is generally attributable to previous pregnancies, and these patients generally have a greater body mass index than the patients who undergo liposuction only. This surgical combination has been performed for 404 patients during the past 8 years. For all these patients, circumferential liposuction extracted more than 1,500 ml of fat. Patients with less than 1,500 ml of fat removal were not included in this study. The range of liposuctioned material, including infranatant and supranatant, was between 2,400 and 14,800 ml (mean, 4,900 ml), whereas the

range of the fat suctioned (supranatant material) was between 1,500 and 8,200 ml (mean 3,700 ml). The amount of flap eliminated fluctuated between 380 and 5,100 g (mean, 870 g). Our complications are included in the liposuction group data because all these patients had liposuction at the same time. No complications were seen in 325 patients (80.4%). Minor complications such as seromas, palpable or visible irregularities, hyperpigmentation, asymmetry of scars, overcorrection, cutaneous slough, and local scars occurred in 75 patients (18.5 %).

Major complications occurred in four patients (0.99%). Of the four patients who experienced major complications, one had fat embolism syndrome. This patient had gluteal lipoinjection at the same time. Another patient had cutaneous necrosis in different areas of the liposuctioned area. This patient had undergone two previous liposuctions. The final two patients had an infection localized to the drainage areas of the lumbar region. The infection appeared on postoperative day 12. All the cases resolved satisfactorily. The management, evolution, and probable cause of each complication are beyond the scope of this study and are discussed in another article.

Marking is identical to the usual liposuction design in the posterior region. In the anterior region, which is to be detached during abdominoplasty, liposuction also is performed. The liposuction technique is identical to that mentioned earlier. With the patient in the dorsal decubital position, liposuction is performed on the flanks, and actually is performed also on the detached abdominal flap. Abdominoplasty is achieved by detaching a tunnel just ample enough to allow

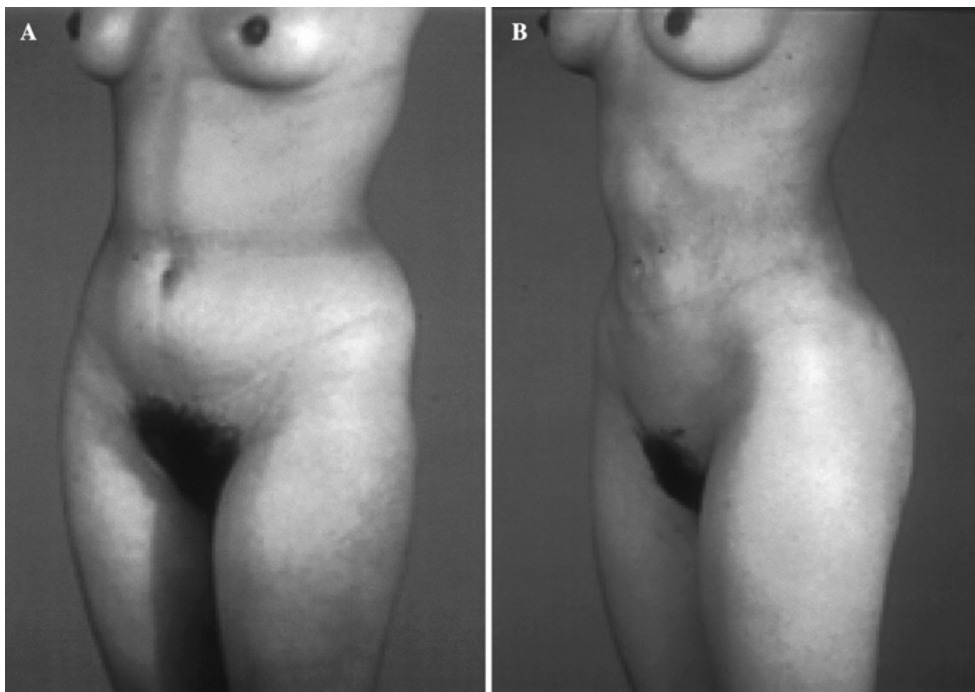


Fig. 3. A 22-year-old woman treated exclusively with liposuction achieved an adequate contour with an acceptable cutaneous retraction.

plication of the abdominal rectus muscles. This plication is performed in two planes using absorbable and nonabsorbable sutures. The postoperative management is similar to that mentioned for liposuction, and the results obtained may be seen in Figs. 4 and 5.

Liposuction, Abdominoplasty, and Breast Surgery

Improvements to the thoracoabdominal contour, with either an isolated liposuction or liposuction combined with abdominoplasty, also may be complemented with breast surgery at the same time to improve the aesthetic result. This combination is less common than abdominoplasty and liposuction alone, but the rate of complications is similar to the rate for those surgeries. The breast surgery can consist of breast augmentation, breast reduction, or breast pexia with or without implants. Breast surgery generally is performed after liposuction, or before abdominoplasty. The results from the combination of these procedures may be seen in Figs. 6, 7, and 8.

Gluteoplasty

Improvement of the gluteal contour can be attained through augmentation of the gluteal region by means of alloplastic implants or fat infiltration. Each of these alternatives has its own precise indications, and both give excellent results [8,15,18,26,32]. Equally, each of these alternatives may be combined with

liposuction to improve the peripheral gluteal contour, which produces an even better result [8]. Our clinical experience with the combination of liposuction and lipoinjection includes 179 patients: 170 females and 9 males. We have performed liposuction on the lumbar, subgluteal, and trochanteric areas for 100%, 86%, and 68% of the patients, respectively. Fat infiltration varied between 120 and 280 ml per buttock (median, 195 ml). Our main complications in this group were the two embolism syndromes mentioned for the liposuction group and the abdominoplasty and liposuction group. Currently, we do not have scientific evidence for a direct relation between fat infiltration and fat embolism syndrome. The other two minor complications associated directly with the lipoinjection were fat necrosis (3 patients) and gluteal erythema (13 patients). Both problems were resolved satisfactorily.

Gluteal augmentation and liposuction of the lumbar region have been performed for 34 patients. Four complications have occurred. One gluteal implant was palpable because it was placed too superficially. Another patient had a slight asymmetry secondary to implant displacement. A unilateral seroma appearing in one patient 1 year after surgery was drained in the operating room. The last complication, a hematoma on the surgical incision that did not affect the implant, was resolved with conservative treatment. The surgical techniques for each of these procedures have been described previously [8,15,18,26,32]. At this point, it is important to emphasize that the gluteal implant is recommended for thin patients without a large

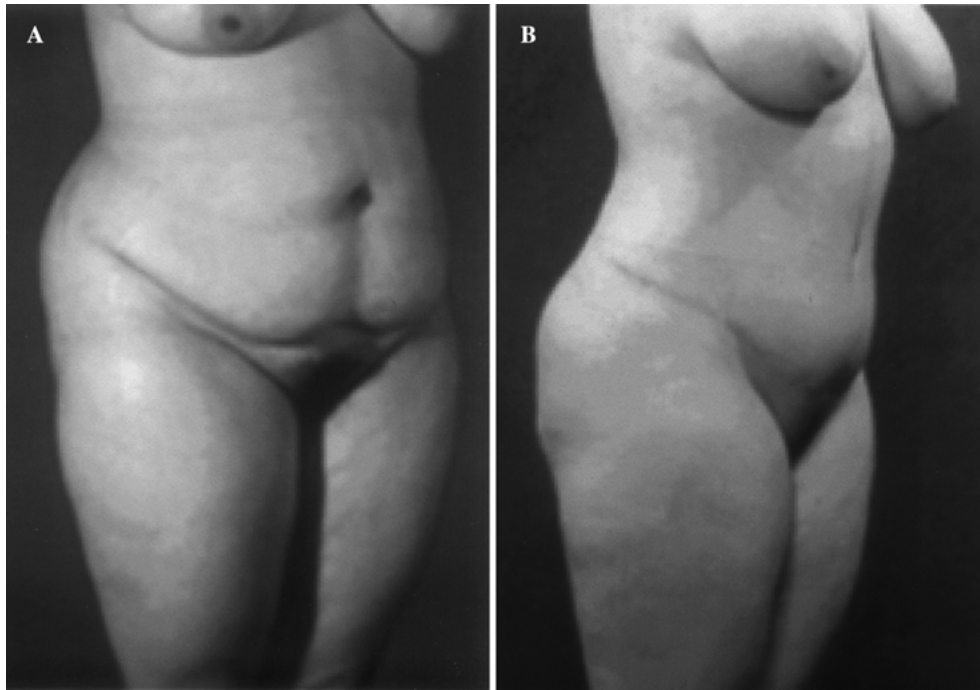


Fig. 4. A 39-year-old woman presented with adequate skin quality and severe abdominal flaccidity. The combination of abdominoplasty with liposuction provided a greater improvement in the abdominal contour.

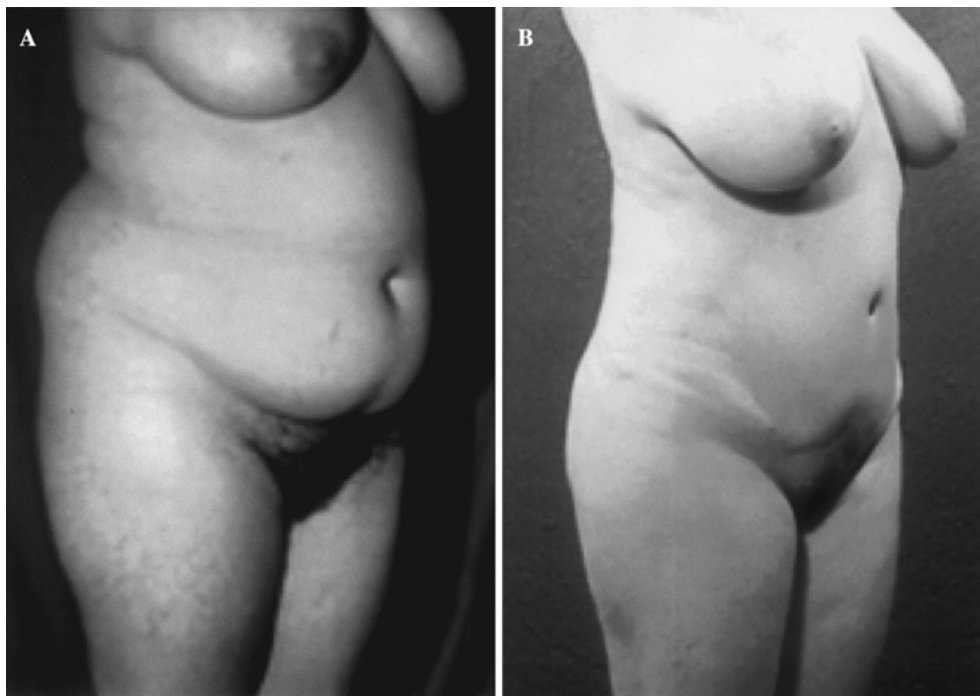


Fig. 5. A 35-year-old woman with regular skin quality achieved an excellent contour at the thoracoabdominal level when treated with a combination of liposuction and abdominoplasty.

amount of lipodystrophy, whereas peripheral fat infiltration with liposuction is recommended for patients with significant lipodystrophy, in whom the fat

may be molded to improve the gluteal contour. The results of combining these techniques can be seen in Figs. 9 and 10.

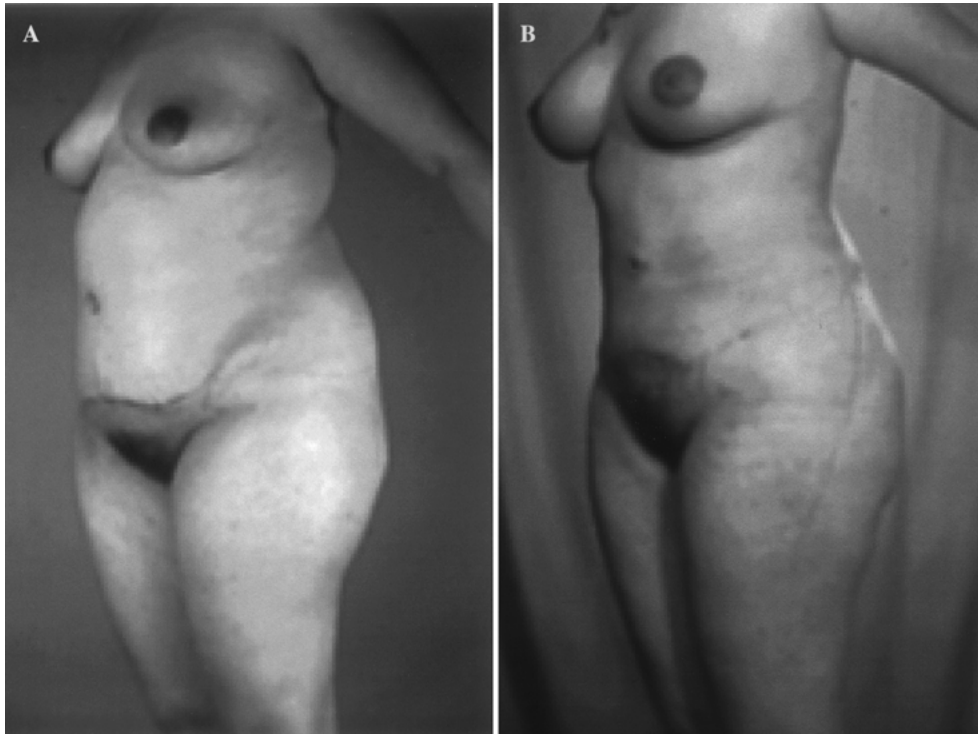


Fig. 6. A 24-year-old woman previously underwent an abdominoplasty. A combination of liposuction with breast implants produced a harmonious body contour.

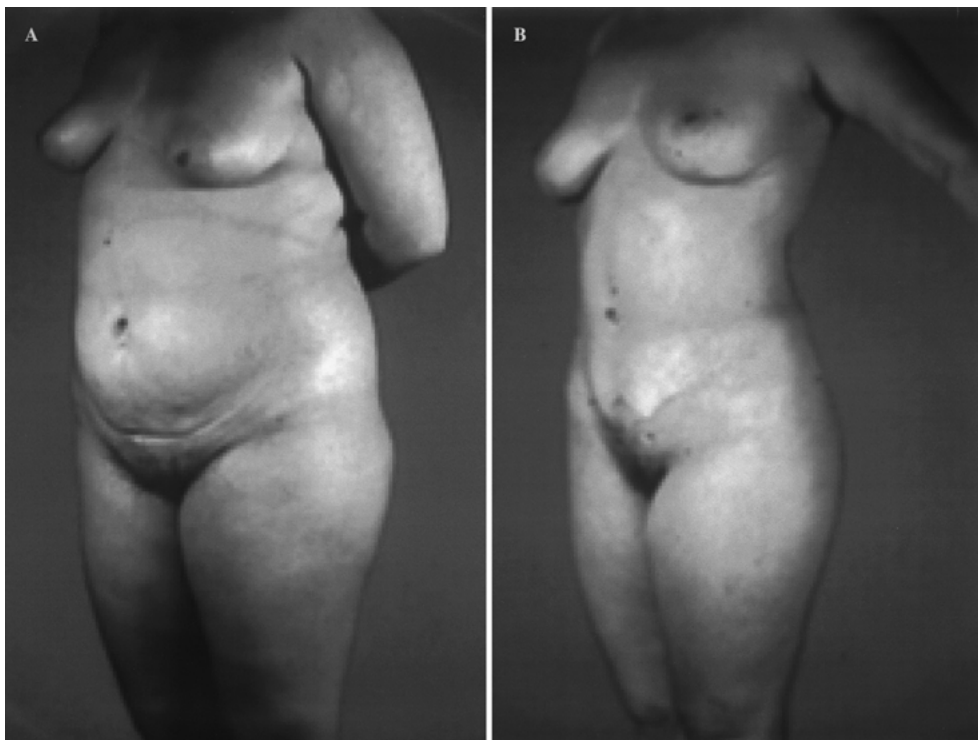

Fig. 7. A 39-year-old woman presented with thoracoabdominal lipodystrophy and mammary ptosis. The combination of mammopexy, abdominoplasty, and thoracoabdominal liposuction notably improved the contour.

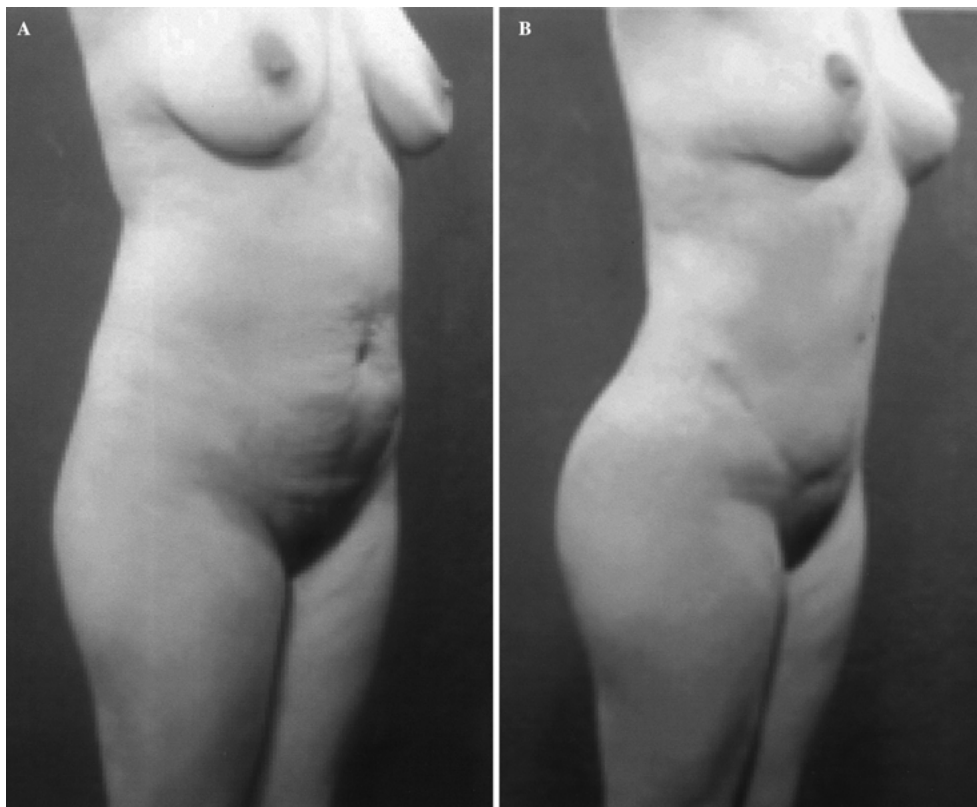


Fig. 8. A 31-year-old woman presented with moderate body lipodystrophy as well as mammary ptosis and abdominal flaccidity. Her improvement was achieved with a combination of abdominoplasty, liposuction, and mammopexy during the same surgery.

Discussion

Body contour surgery has become the most common surgery performed by plastic surgeons [29]. The alternatives and procedures for body contouring surgery are numerous and variable [2–4,8,12,14–16,18–20,23,24,26,30,32]. Because of this, correct procedural selection is one of the most important aspects for consideration to guarantee surgical success.

Routinely, contour-improving techniques are combined to achieve a more harmonious result. Therefore, it is possible to combine procedures in the same body region and in different areas to achieve this objective [3,7,8,12,15,23,24,27]. Usually, the basic procedure is liposuction because it can be used to resolve a myriad of contour problems [1,3,7,11,18,29]. Liposuction is a very good surgical option although patients exhibit a significant degree of flaccidity attributable to lipodystrophy, because cutaneous retraction always favorably influences the final result [1,9]. Nevertheless, this should not be interpreted as a factor in every case if the procedural choice is not appropriate. If a patient has significant flaccidity, the procedure of choice should be one that eliminates this tissue excess. For these cases, the basic surgical procedure is dermolipec-

tomy [2,10,12,19,24,30], which usually is performed in the abdominal region, and which may furthermore be combined with liposuction to eliminate fat [7].

This same concept may be applied to the gluteal region, in which the main defect is lack of volume. This volume deficit may be compensated through the placement of gluteal implants [32] or by fat infiltration [8,15,18,26]. The results of gluteal implants are more predictable and more homogeneous [32]. Nevertheless, the principal disadvantage is an aversion of many patients to the placement of alloplastic material in their body, and also the cost of the procedure. Fat infiltration constitutes a viable alternative for these patients, and it also gives very satisfactory results [8,15,18,26]. But as with gluteal implants, there are several disadvantages, such as reabsorption in a variable percentage of patients, and the possibility of tissue irritation and calcifications resulting from fat that is infiltrated [8]. Similarly, fat infiltration has a very precise indication for patients in whom a prior body contouring permits us to achieve molding by combining this technique with liposuction in the gluteal periphery [8]. This same combination with liposuction may be used for patients receiving gluteal implants, thereby improving the final result.

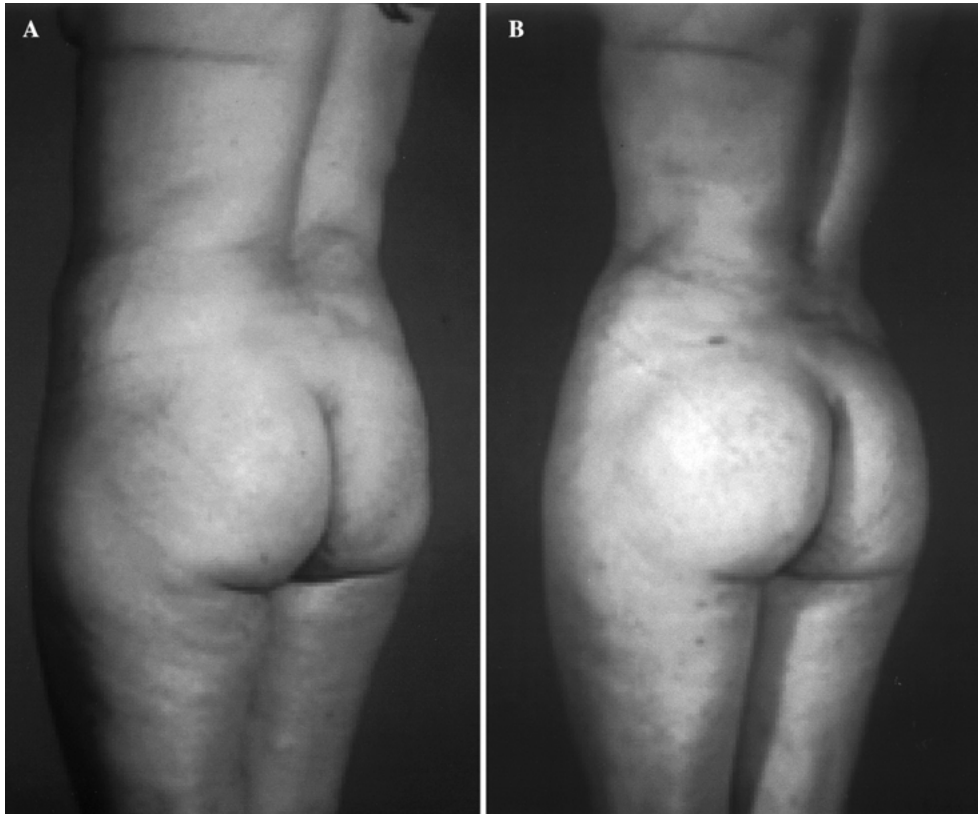


Fig. 9. A 34-year-old woman with corporal lipodystrophy and moderate gluteal hypoplasia was treated with liposuction and fat infiltration in the gluteal region and achieved an excellent result.

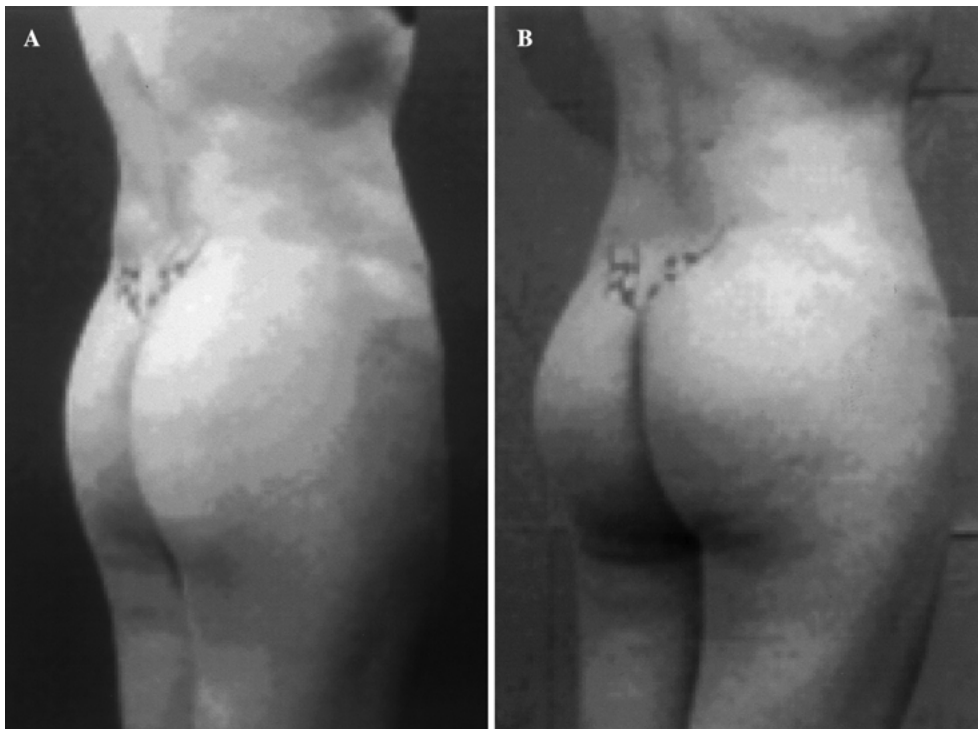


Fig. 10. A 29-year-old woman presented with gluteal hypoplasia and minimal lipodystrophy. The patient was managed with gluteal implants combined with slight liposuction, which produced a very good result.

Either of these procedures may be combined with breast surgery when needed. Breast procedures are multiple and varied, comprising a number of alternatives [13,14,17,20,28]. Similarly, placement of implants can be performed only with round or anatomically shaped implants [22,25], or if the breast presents a certain degree of ptosis, mammopexy can be performed [20,28] using whichever technique is indicated. This mammopexy should be combined conjointly with the placement of implants if a certain degree of mammary hypotrophy exists, and depending on the condition of the mammary tissue [17]. Of course, the need to perform a reduction mammoplasty should not be forgotten when breast size is out of proportion with the patient's new aesthetic contour [14,28].

One of the most important factors for surgeons to consider when performing a body contour surgery is whether the procedure can be performed during a single surgical session, or whether it will require several sessions. Each choice has its advantages and disadvantages. We prefer to perform the procedures in one surgical session, but several details must be observed. The patient must be in optimal health to undergo the procedure during one surgical session. An autotransfusion of blood should be considered for extensive procedures during which considerable blood loss is expected. We always perform this kind of surgery using at least two assistant surgeons in addition to the primary surgeon and surgical instrumentist. Sometimes a third assistant surgeon is needed. This significantly shortens surgical time, which benefits the patient. The assistant surgeons are always under the coordination of the primary surgeon, who ensures that management will result in the expected final result.

Despite all this, on occasion body contouring procedures must be performed during two or up to three surgical sessions, depending on the surgical judgment of the surgeon. The most important aspect should be the choice of the surgical procedure to be performed depending on each particular case. Body contour surgery is the most frequently performed [29], which doubtlessly is because of the excellent results and the low rate of complications if a good surgical selection is made.

References

- Alegria Peren P, Barba Gomez J, Guerrero-Santos J: Total corporal contouring with megaliposuction (120 consecutive cases). *Aesth Plast Surg* **23**:93–100, 1999
- Aly AS, Cram AE, Chao M, Pang J, McKeon M: Belt lipectomy for circumferential truncal excess: the University of Iowa experience. *Plast Reconstr Surg* **111**:398–413, 2003
- Baroudi R: Body sculpturing. *Clin Plast Surg* **11**:419–443, 1984
- Bricout N: *Breast augmentation in breast surgery of Bricout N*. Ed Springer-Verlag: Paris, France, 1992
- Cardenas-Camarena L, Andino-Ulloa R, Mora RC, Fajardo-Barajas D: Laboratorial and histopathological comparative study between internal ultrasound-assisted lipoplasty and tumescent lipoplasty. *Plast Reconstr Surg* **110**:1158–1164, 2002
- Cardenas-Camarena L, Cardenas A, Fajardo-Barajas D: Clinical and histopathological analysis of tissue retraction in tumescent liposuction assisted by external ultrasound. *Ann Plast Surg* **46**:287–292, 2001
- Cardenas-Camarena L, Gonzalez LE: Large-volume liposuction and extensive abdominoplasty: A feasible alternative for improving body shape. *Plast Reconstr Surg* **102**:1698–1707, 1998
- Cardenas-Camarena L, Lacouture AM, Tobar-Losada A: Combined gluteoplasty: Liposuction and lipoinjection. *Plast Reconstr Surg* **104**:1524–1531 discussion 1532–1533, 1999
- Cardenas-Camarena L, Tobar-Losada A, Lacouture AM: Large-volume circumferential liposuction with tumescent technique: A sure and viable procedure. *Plast Reconstr Surg* **104**:1887–1899, 1999
- Carwell GR, Horton CE Sr: Circumferential torsoplasty. *Ann Plast Surg* **38**:213–216, 1997
- Commons GW, Halperin B, Chang CC: Large-volume liposuction: A review of 631 consecutive cases over 12 years. *Plast Reconstr Surg* **108**:1753–1763, discussion 1764–1767, 2001
- Erni D, Banic A: Body contouring by removal of skin and fatty tissue. *Ther Umsch* **56**:206–211, 1999
- Glicenstein J: History of breast augmentation. *Chirurgie* **119**:611–613, 1993–1994
- Goldwyn RM: Reduction mammoplasty: A personal overview in reduction mamaplasty of Goldwyn RM Little Brown and Company: Boston, 1990
- Guerrerosantos J: Autologous fat grafting for body contouring. *Clin Plast Surg* **23**:619–631, 1996
- Illouz YG: Body contouring by lipolysis: A 5-year experience with over 3,000 cases. *Plast Reconstr Surg* **72**:591–597, 1983
- Karnes J, Morrison W, Salisbury M, Schaeferle M, Beckham P, Ersek RA: Simultaneous breast augmentation and lift. *Aesth Plast Surg* **24**:148–154, 2000
- Lack EB: Contouring the female buttocks: Liposculpting the buttocks. *Dermatol Clin* **17**:815–822, vi, 1999
- Lockwood T: Lower body lift with superficial fascial system suspension. *Plast Reconstr Surg* **92**:1112–1122, discussion 1123–1125, 1993
- Lockwood T: Reduction mammoplasty and mastopexy with superficial fascial system suspension. *Plast Reconstr Surg* **103**:1411–1420, 1999
- Lockwood T: The role of excisional lifting in body contour surgery. *Clin Plast Surg* **23**:695–712, 1996
- Mladick R: Textured silicone breast implants. *Plast Reconstr Surg* **110**:1201–1202, 2002
- Mladick RA: Advances in liposuction contouring of calves and ankles. *Plast Reconstr Surg* **104**:823–831 discussion 832–833, 1999
- Morales Gracia HJ: Circular lipectomy with lateral thigh-buttock lift. *Aesth Plast Surg* **27**:50–57, 2003
- Niechajev I: Anatomical breast implants: Different experience. *Plast Reconstr Surg* **112**:1186–1187, 2003
- Peren PA, Gomez JB, Guerrero-santos J, Salazar CA: Gluteus augmentation with fat grafting. *Aesth Plast Surg* **24**:412–417, 2000

27. Pitanguy I: Evaluation of body contouring surgery today: A 30-year perspective. *Plast Reconstr Surg* **105**:1499–1514discussion 1515–1561, 2000
28. Pitanguy I: Surgical treatment of breast hypertrophy. *Br J Plast Surg* **20**:78–85, 1967
29. Accessed at http://www.plasticsurgery.org/public_education/loader.cfm?url=/commonspot/security/get-file.cfm & page ID = 16158
30. Van Geertruyden JP, Vandeweyer E, de Fontaine S, Goldschmidt DP: Duchateau: Circumferential torso-plasty. *J Br J Plast Surg* **52**:623–628, 1999
31. Van Zele D , Heymans O: Breast implants: A review. *Acta Chir Belg* **104**:158–165, 2004
32. Vergara R, Marcos M: Intramuscular gluteal implants. *Aesth Plast Surg* **20**:259–262, 1996