

# Deforming Posttraumatic Hematoma of the Nasal Tip: An Infrequent Lesion

Miguel Ángel León, M.D., and Lázaro Cárdenas-Camarena, M.D.

Guadalajara, Mexico

Because of its anatomical location, the nose is one of the body regions that most frequently experience trauma.<sup>1</sup> For this reason, it is also the area of the face that most frequently experiences fractures,<sup>1,2</sup> although the fracture of nasal bones, simple or complex,<sup>3</sup> is not the only consequence that can accompany trauma.<sup>1-9</sup> Among the most important secondary effects of nasal trauma is vascular damage without drainage, which is complicated by the formation of a hematoma.<sup>1-3</sup> Nasal hematomas are principally found at the nasal septal level and, if not treated adequately, can present severe complications.<sup>1-10</sup> Very few cases of nasal hematomas affecting other areas of the nasal septum have been reported,<sup>11,12</sup> and to date, no report exists in which the lesion was diffusely present at the level of the entire nasal tip. We present a case of a deforming hematoma of the nasal tip with a lesion of the alar cartilage, which appeared following a slight nasal tip trauma. The hematoma was not diagnosed early because this type of lesion following nasal trauma was not considered a possibility, and because of the characteristics of the lesion, it was inadequately treated initially. Emphasis should be placed on the importance of early diagnosis and treatment in this type of lesion to maximally prevent aesthetic complications and alterations.

### CASE REPORT

A 23-year-old woman sought medical consultation for swelling and deformity on the nasal tip. The medical history revealed that she had received a blow to the nasal region by her 8-month-old infant's head. Several days following the blow, the patient experienced progressive swelling of the nasal tip without evident bleeding. She sought consultation with us 2 months after the incident, after having sought several other medical evaluations. Following all previous med-

ical evaluations, anti-inflammatory therapy was prescribed based on the medical history and the clinical evolution. The main diagnosis was posttraumatic swelling, but the problem persisted. We saw the patient with a serious nasal respiratory obstruction accompanied by a large deformity of the soft tissues of the nasal tip. Physical examination revealed collapse of the internal nasal valve bilaterally, with increased size, inflammation of the septal mucosa, respiratory obstruction, and a significant increase in volume with deformity of all the nasal structures (Figs. 1 and 2, *left*). The complete blood count and chemical analyses showed no abnormalities and did not reveal any blood dyscrasias. The computed tomographic scan revealed irregular borders of the distal nasal bones accompanied by severe swelling of the soft tissues on the dorsum of the nasal pyramid, with prominence toward the right (Fig. 2, *right*). An increased volume was also observed on the superior portion of the cartilaginous septum, which produced contact between the septum and the internal valve region. No calcifications, foreign bodies, septum deviations, turbinate alterations, or components of an infiltrating lesion were observed. A surgical exploration was performed using inhaled general anesthesia to determine the cause of the swollen mass. After previously infiltrating the nasal tip and distal septum with lidocaine and epinephrine at 1:200,000, we proceeded to explore the nasal tip using an open approach through transcolumar and marginal incisions. Using this approach, we explored the superior and inferior lateral cartilages and found a loss of continuity of the alar cartilages and severe deformity of the same, with swelling of the septal mucosa. We also found a large amount of granulomatous tissue with hemorrhagic characteristics all around the nasal tip, caudal septum, and nasal dorsum; this tissue was removed with the largest extension possible. The septum affected by the lesion was thinner than the rest but did not appear to have support problems. The alar cartilages were repaired with 6-0 nylon sutures to restore their continuity. The nasal mucosa was closed with 5-0 chromic sutures, and the transcolumar incision was closed with 6-0 nylon sutures. Histologically, we found severe chronic inflammatory changes consistent with mature lymphocytes that were dispersed, with granular tissue and neovascularization. Granular posttraumatic tissue without any evidence of malignant cells or microorganisms was reported. The patient demonstrated significant aesthetic improvement 3 months postoperatively, and the nasal tip prob-

From the Departments of Plastic and Reconstructive Surgery of the New Civil Hospital of Guadalajara and the Jalisco Reconstructive Surgery Institute. Received for publication September 17, 2002; revised April 3, 2003.

DOI: 10.1097/01.PRS.0000101531.31293.F5

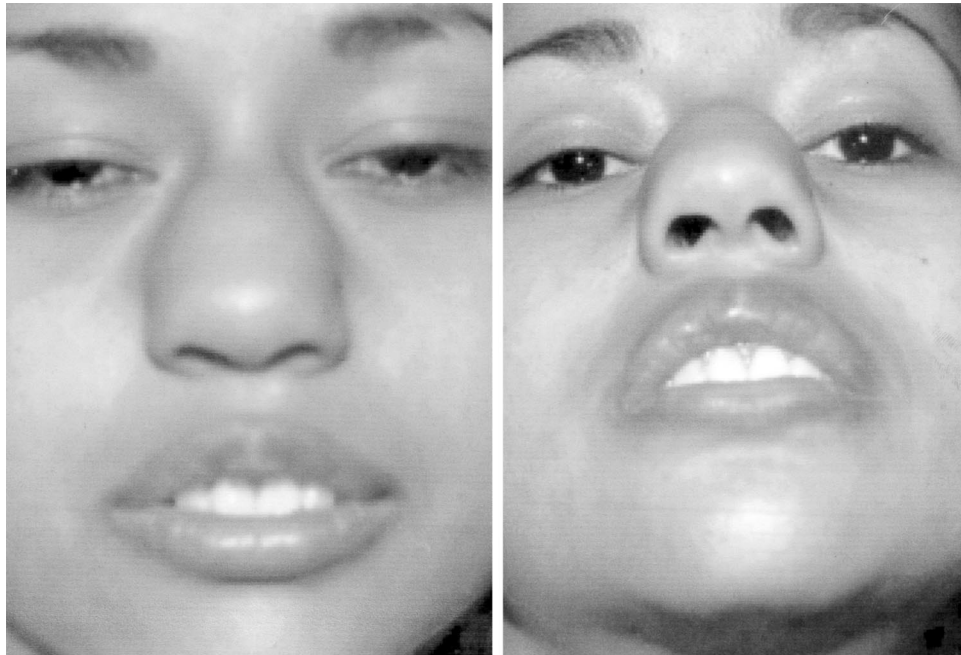

FIG. 1. Preoperative (*Left*) frontal and (*right*) basal views of the patient, showing prominent deformity of the nose.

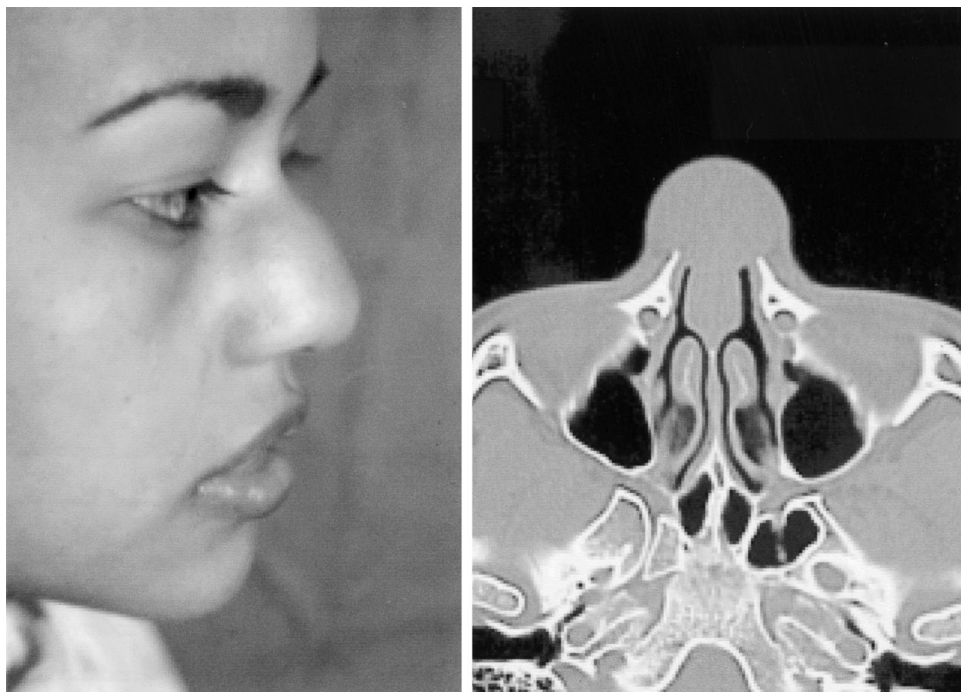


FIG. 2. (*Left*) Preoperative lateral view of the patient. (*Right*) Computed tomographic image showing increased volume on the anterior portion of the cartilaginous septum and on the nasal tip.

blem was resolved (Figs. 3 and 4). At 10-month follow-up, the patient continued to experience no problems.

#### DISCUSSION

Trauma around the nasal region is a common problem.<sup>1-3</sup> Its high incidence is due to the nose's position in the center of the face.<sup>1</sup>

Because of the anatomical characteristics of the nasal bones and the poor support that the septal cartilage offers, lesions to these structures are very common following nasal trauma.<sup>1,2</sup> Lesions of the nasal bones and septal cartilage can be of a combined or isolated

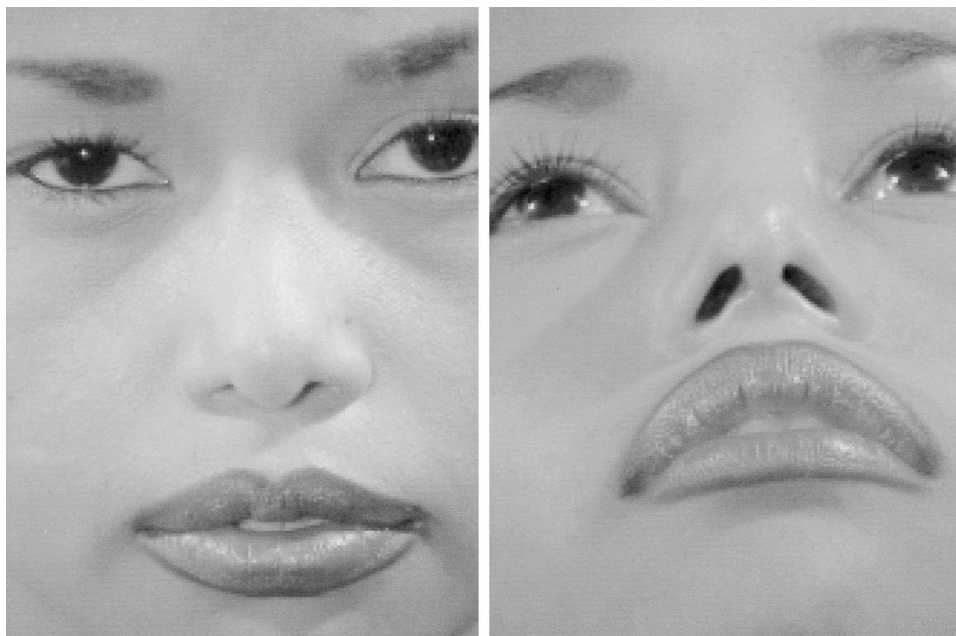

FIG. 3. Postoperative (*left*) frontal and (*right*) basal views of the patient, showing notable improvement of the nose.




FIG. 4. Postoperative lateral view of the patient.

form, depending on multiple factors.<sup>3</sup> The septal cartilage lesion can be manifested in a simple form, which is more common,<sup>3</sup> or it can be accompanied by other alterations that completely change its management. A septal hematoma is one of the most serious lesions that can accompany a septal cartilage lesion and should be considered a medical emergency.<sup>1-4,8,9</sup>

A septal hematoma is an infrequent complication,<sup>7,8</sup> secondary to bleeding between the cartilage and the mucoperichondria.<sup>3</sup> Its presence is generally secondary to nasal trauma,<sup>1-4</sup> which can inclusively be slight,<sup>6,9</sup> although there are reports of spontaneous nontraumatic etiologies.<sup>7</sup> If the hematoma is not evacuated, it could evolve into different forms. Less problematic is its self-organization with the formation of fibrous tissue, thickening of the septum, and posterior obstruction of the nasal air passage.<sup>3,9</sup> On other occasions, it produces weakness in the septal cartilage secondary to inadequate vascularization<sup>3</sup> or a true necrosis that produces deforming aesthetics of the nose.<sup>1-4,8,9</sup> If not treated, the hematoma can become infected, and severe complications can develop, ranging from a severe aesthetic deformity<sup>3,4,6,9</sup> to an intracranial infection<sup>10</sup> to death due to a cerebral abscess.<sup>7</sup> For this reason, surgical treatment should be immediate to achieve drainage and to avoid more serious complications.<sup>1-4,8,9</sup> It is also recommended that antibiotic therapy be combined with the surgical management.<sup>8,9</sup>

Even though there have been many reports of septal hematoma following nasal trauma, there are only few reports of hematomas in other regions of the nose secondary to trauma.<sup>11,12</sup> Less frequent is the presence of hematomas affecting the lateral cartilages; to date, fewer than 10 reported cases exist in the world literature.<sup>12</sup> In these cases, the predisposing

cause was always nasal trauma, with the majority of these cases occurring in children.<sup>11</sup> Usually the clinical data on these lesions are not as severe as with the existence of a septal hematoma, because they sometimes are present as a small mass in the nasal vestibule.<sup>12</sup> Nevertheless, on occasion, the reaction and evolution are similar to those of a septal hematoma, accompanied by a severe deformity when treatment is delayed.<sup>12</sup> Therefore, treatment is immediate surgery. In contrast to reports in the world literature, our patient's illness was severe over the nasal tip, with the lesion extending to the alar cartilages and anterior septum. Although a history of direct trauma to the nasal region was present, this was not severe. This fact, along with the slow evolution of the clinical history and the lack of concluding data in the previous clinical studies, made an early diagnosis difficult. It was the suspicion of a probable organized hematoma that influenced our surgical treatment with an ample incision of the nasal region. The hematoma was found to be diffuse in the entire tip and the dorsal portion of the nasal septum. Given the analysis of the affected nasal areas and the extent of the problem, the vessels that were probably affected were the nasal branches of the anterior ethmoidal artery, which is a branch of the ophthalmic artery that extends from the internal carotid artery. The nasal branches of the anterior ethmoidal artery irrigate the anterior septum and the lateral nasal area. Also, the alar region was affected by the hematoma, so the facial artery through the septal and alar branches could have contributed to the problem. The low incidence of this type of lesion led the patient to seek medical attention at various clinics without a precise diagnosis being made, which delayed early definitive treatment. Because of the large existing deformity, during the operation, we removed the lesion of the nasal tip and nasal dorsum as amply as possible and repaired the evident lesions of the affected structures. Although the resulting nasal tip was acceptable, the septal cartilaginous support was lost in the distal portion and will require future treatment for a complete correction. This lost support was probably secondary to cartilage weakening resulting from delayed treatment, but it was not evident at the operation because of the soft-tissue swelling.

Traumatic nasal lesions are very frequent, and may present differing complications. The appearance of hematomas secondary to

trauma is rare, but when it does occur, it affects the cartilaginous portions of the septum. A hematoma affecting other areas is extremely rare, which makes diagnosis difficult, especially when its evolution is slow; the hematoma can also be confused with a tumor.<sup>13</sup> Nevertheless, the deformities and consequences that may occur are equally severe when a hematoma exists in the septal cartilage region. Therefore, one should always consider that a hematoma may be present following nasal trauma and can affect any nasal anatomic region. Surgery is the treatment of choice, with maximal exposure of the nasal structures, if indicated.

Miguel Ángel León, M.D.

New Civil Hospital of Guadalajara

Herrera y Cairo 2691-4

Col. Providencia Sur

Guadalajara, Jalisco 44600

Mexico

leonmiguelangel@terra.com.mx

#### REFERENCES

1. Mathog, R. H. Nasal fractures. In R. H. Mathog (Ed.), *Atlas of Craniofacial Trauma*. Philadelphia: Saunders, 1992.
2. Kastenbauer, E. R., and Masing, H. Intranasal surgery and the management of acute nasal injuries. In M. E. Tardy and E. R. Kastenbauer (Eds.), *Head and Neck Surgery: Face, Nose And Facial Skull, Part I*, Vol. 1. New York: Thieme Medical Publishers, 1995.
3. Converse, J. M., and Dingman, R. O. The clinical management of facial injuries and fractures of the facial bones. In J. M. Converse (Ed.), *Reconstructive Plastic Surgery*, Vol. 2. Philadelphia: Saunders, 1977.
4. Kryger, H., and Dommerby, H. Haematoma and abscess of the nasal septum. *Clin. Otolaryngol.* 12: 125, 1987.
5. Matsuba, H. M., and Thawley, S. E. Nasal septal abscess: Unusual causes, complications, treatment, and sequelae. *Ann. Plast. Surg.* 16: 161, 1986.
6. Alvarez, H., Osorio, J., De Diego, J. I., Prim, M. P., de la Torre, C., and Gavilan, J. Sequelae after nasal septum injuries in children. *Auris Nasus Larynx* 27: 339, 2000.
7. Chukuezi, A. B. Nasal septal haematoma in Nigeria. *J. Laryngol. Otol.* 106: 396, 1992.
8. Ginsburg, C. M. Nasal septal hematoma. *Pediatr. Rev.* 19: 142, 1998.
9. Lopez, M. A., Liu, J. H., Hartley, B. E., and Myer, C. M. Septal hematoma and abscess after nasal trauma. *Clin. Pediatr. (Phila.)* 39: 609, 2000.
10. Jalaludin, M. A. Nasal septal abscess: Retrospective analysis of 14 cases from University Hospital, Kuala Lumpur. *Singapore Med. J.* 34: 435, 1993.
11. Meehan, T., Kaddour, H., and Lannigan, F. J. Alar cartilage haematoma. *J. Laryngol. Otol.* 108: 500, 1994.
12. Green, K. M., Board, T., and Mason, J. D. Alar haematoma. *J. Laryngol. Otol.* 113: 1104, 1999.
13. Unlu, H. H., Mutlu, C., Ayhan, S., and Tarhan, S. Organized hematoma of the maxillary sinus mimicking tumor. *Auris Nasus Larynx* 28: 253, 2001.